Following pdfs notes are available free →
1 → marrow edition 4 notes(latest optha notes also available) , marrow qbank , marrow pearls
2-> prepladder notes, prep rapid revision 2.0,prepladder treasures 3-> Notespaedia devesh mishra pathology notes, notespaedia marrow Ecg, Notespaedia elite optha
For more
4-> egurukul - - >aswini Kumar anatomy notes, dermatology notes, medicine by thameem sir, ortho notes, physio notes, radio notes(all by notespaedia)
5->all standards books and review books Telegram - @latestpgnotes
6->Notes on demand and many more premium notes are will available free very soon Telegram : @latestpgnotes For more latest notes, join the telegram channel @latestpgnotes
For neet pg discussions join telegram group @neetpgdiscussion
For more latest notes, join the telegram channel @latestpgnotes
Click on link below to join our telegram channel

For more latest notes, join the telegram channel @latestpgnotes For neet pg discussions join telegram group @neetpgdiscussion For group discount upto 40-50% on any lecture app or individual app dm @drnash1

FREE PDF DOWNLOAD
Click here
Click here join Now
Telegram

HEART SOUNDS - S_1

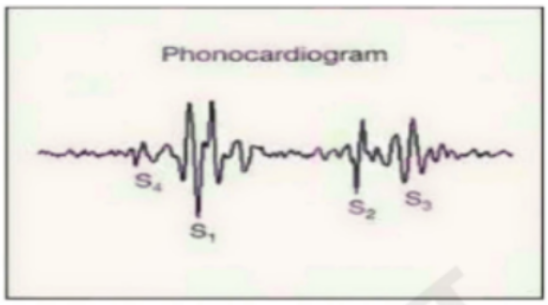

- In phonocardiogram →
  - S_1 has got 2 major vibration in it.
  - 1st vibration mainly occur d/t muscle activity.
  - S_1 is slightly broader than S_2 but S_2 is more sharper in nature than S_1.

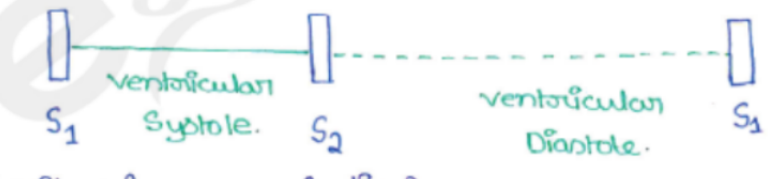

Mitral & Tricuspid Valve Closed

Aortic & Pulmonary Valve Closed.

Telegram - @Latestpgnotes

- Ventricular diastole divided into 3 phases —
  - (I) Isovolumetric relaxation.
  - (II) Early diastolic (Passive) filling of ventricle.
  - (III) Atrial Contraction.
- During diastole can hear some additional sounds — S_3 & S_4.
  - Low pitched sound
  - Heard in Localized area.
  - Heard best via bell of steth.

THE CARDIAC CYCLE

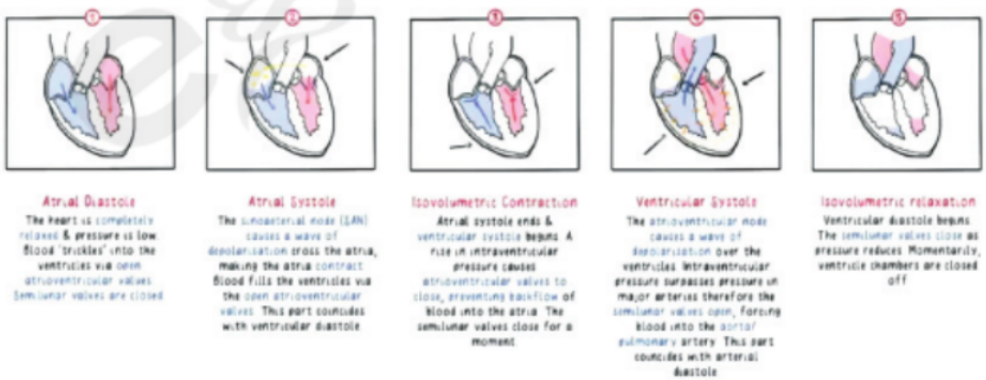

Telegram - @Latestpgnotes

- S_1 → Occur during isovolumetric Contraction.
  d/t Closure of – Mitral & Tricuspid valve.

- S_2 → Occur at end of ventricular Systole.
  d/t Closure of – Aortic & pulmonary valve.

- S_3 → Occur d/t passive filling of blood during ventricular diastole.

- S_4 → Occur d/t Atrial Contraction.

⊛ 1ST HEART SOUND (S_1)

- 1st vibration → Low frequency vibration.
  Occur d/t – LV Contraction.
  (Muscular in origin).

- 2nd vibration → Occur d/t – Closure of mitral & tricuspid valve.
  High frequency vibration.

Telegram - @Latestpgnotes

• Correlation of ECG —

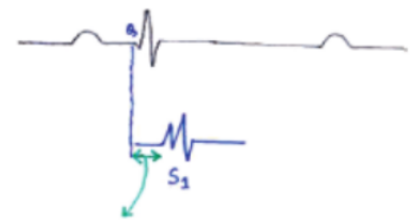

Time → 50 ms.

It is the time required for the current to spread across the ventricle & the muscle to contract.

✱ Factors That Determine Intensity Of S_1

- Structural integrity of AV-valves.
- Velocity of closure of MV.
- Status of ventricular contraction.
- Physical characteristics.
- Transmission characteristics.
- Position of valves at the point of ventricular contraction initiation.
- Crossover of pressure from ventricle to atria.

Telegram - @Latestpgnotes

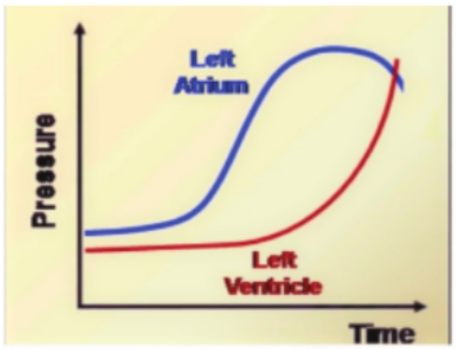

✳ TIMING OF S_1

- Timed ≅ palpation of carotid pulse or apical impulse.

✳ CHARACTERISTICS OF S_1

- Medium to High frequency.
- Low-pitched sound
- S_1 splitting best heard → Medial to apex. (closure to Lt. lower sternal border).

↓

Because T_1 is very soft near apex but it is louder near Lt. lower sternal border

- S_1-Splitting best heard during – Expiration.

Telegram - @Latestpgnotes

✳ Loud S_1

- Exercise.
- Emotional excitability.
- Mitral stenosis.
- Atrial septal defect
- Sinus tachycardia.
- Short PR-interval (d/t hyperkinetic state).

✳ Soft S_1

- Mitral regurgitation
- Aortic regurgitation.
- Ventricular aneurysm
- Acute MI.
- Myocarditis.
- Cardiomyopathies.
- Calcified mitral valve.
- Any cause of prolonged PR-interval.

✳ In mitral stenosis, Stenotic valve not allow emptying of blood from atria to ventricle.

Telegram - @Latestpgnotes

↓

So, LV got less vol. of blood.

Less the vol. ⟶ more widen the valves are.

So, S_1 become loud.

Also in MS, Atrial pre. is more. So, for ventricles it takes more time to crossover & Resulting in Loud S_1.

⊛ In ASD, Large amount of blood diverted towards RA form LA

↓

So, LV will get less amount of blood.

Results in valves are wide open & Lt Loud S_1.

⊛ In case of Short PR-interval.

↓

Ventricle start contracting while atria is in systole.

So, for ventricles take more time to cross-

Telegram - @Latestpgnotes

- over the pre. of atria. & Lt
Loud S_1.

* In MR, Coaptation of valve not occurring properly. → Lt Soft S_1.

* In AR, Blood coming to LV from LA as well as from aorta.

↓

So, LV filled & more vol. of blood resulting in valves are less widely opened.
Lt - Soft S_1.

* In ventricular aneurysm → Blood is leaking out → Not enough pressure is there in LV.
→ Not enough force is there to shut the valve & resulting in Soft S_1.

* In Acute MI or Myocarditis or Cardiomyopathies

↓

Muscle of the heart is damaged.

↓

Telegram - @Latestpgnotes

So, poor contraction of m. cannot generate enough force to shut the valve.

↓

Lt – Soft S_1.

⊛ In calcified MS, commissures of valve is calcified.

↓

Movement of the valve restricted.

↓

Lt – Soft S_1.

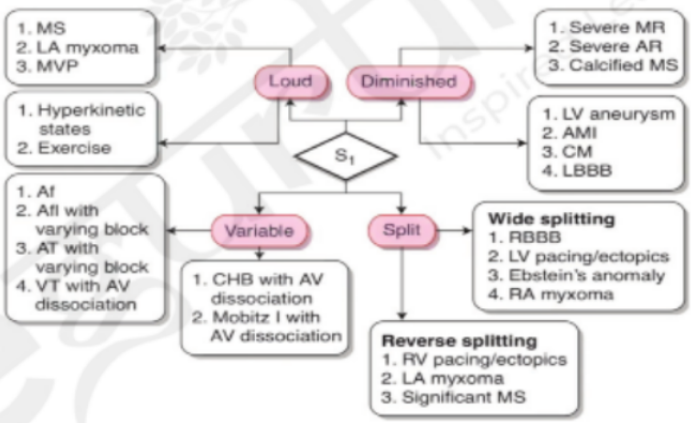

⊛ WIDE SPLITTING – S_1

- RBBB.
- LV-Pacing.
- Ebsteins anomaly.
- Rt. atrial myxoma.

Telegram - @Latestpgnotes

✱ Reverse Splitting - S_1

- RV pacing.
- Lt. atrial myxoma.
- Pt. ☡ significant mitral stenosis.

✱ Variable Intensity of S_1

- Atrial fibrillation.
- Pt. ☡ extrasystole.
- Pt. ☡ complete heart block.

Telegram - @Latestpgnotes

HEART SOUND - S_2

- A_2 & P_2 occur d/t ——

  (I) Abrupt tensing of closed leaflets.

  (II) Vibration created by ⇒

  - Valves
  - Great vessels.
  - Ventricular outflow tract.
  - Decelareting blood mass.

- S_2 ⟶ Medium to high frequency sound.

- Crossover of Aorta - LV / Pulmonary art. - RV pressure precedes semilunar coaptation & cessation of forward flow.

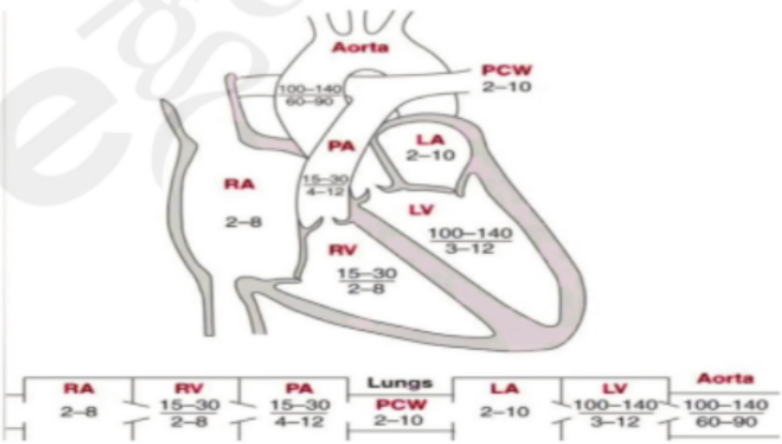

Telegram - @Latestpgnotes

• A_2 occur earlier than P_2.

↓

Difference in pressure gradient b/w aorta & LV is High. So, A_2 occur earlier.

But difference in pressure gradient b/w Pulmonary art. & RV is less. So, P_2 occur later.

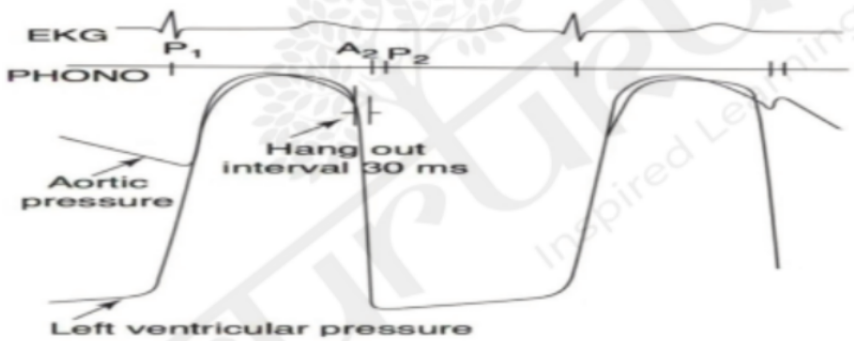

• Hangout Interval ⇒

- The moment aorta pressure is more than LV pressure, valve doesn't shut immediately.

↓

(1) will take 30 ms. time before shut

Telegram - @Latestpgnotes

This interval is C/a – Hangout interval.

It occur because when LV pumped blood into aorta → Created a forward flow inertia & blood should slow down for closing up of valves. So, this slowing down is going to take little time.

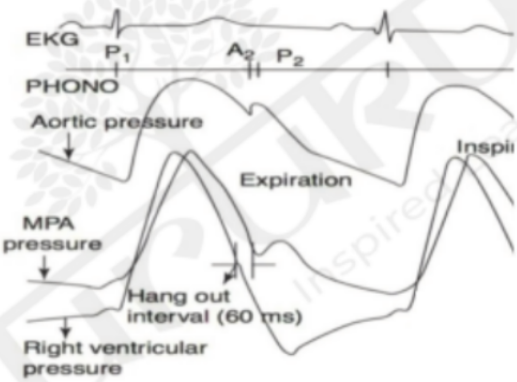

(*) In Rt. side → there is prolonged hangout interval, because —

- Pressure in pulmonary circulation is not much.
- Blood in pulmonary art. takes more time to slow down because of resistance

Telegram - @Latestpgnotes

in pulmonary art. is much lesser.

- Hangout interval of P_2 —
  - During expiration → 60 ms
  - During inspiration → 80 ms.
- P_2 fluctuates / moves more ∈ respiration

  Compare to A_2 —

  1. Resistance in pulmonary circulation varies ∈ respiration.

     Respiratory cycle do not have any impact on aortic pressure.
- A_2 is louder in intensity than P_2 because of —

  1. Stiffer valves.
  2. Vibration generated on aortic side is much more than pulmonary side.

✱ MECHANISM OF A_2-P_2 SPLIT ∈ RESPIRATORY CYCLE

Telegram - @Latestpgnotes

- In inspiration, diaphragm is lowered & Chest goes into negative pressure.

↓

It creates suctioning effect on the thorax & sucking more blood into the heart.

↓

↑ed venous return to Rt. heart. but

↓ed venous return to Lt. heart.

↓

During inspiration → There is longer hangout interval & Amount of blood also more in Rt. side allowing more time to empty out.

D/t these reasons → P_2 get delayed.

- This inspiratory split of A_2-P_2 is —

  Physiological Split.

⊛ Loud A_2

- Systemic HTN
- Dilated ascending aorta.

Telegram - @Latestpgnotes

Eg.→ Aneurysm, Syphillis, etc.

- Transposition of great arteries
- Hyperkinetic circulatory states.

⊛ SOFT A_2

- Aortic sclerosis
- Valvular Aortic Stenosis
- Aortic Regurgitation.

⊛ LOUD P_2

- Pulmonary hypertension.

⊛ SOFT P_2

- Pulmonary Stenosis
- Tetralogy of Fallot.

⊛ WIDE A_2-P_2 SPLIT

- Atrial septal defect
- Ventricular septal defect.
- Mitral Regurgitation
- RBBB.

Telegram - @Latestpgnotes

- Ventricular ectopics.
- Pulmonary stenosis.
- Pulmonary embolism.
- Pulmonary HTN & Rt. heart failure.

⊛ In ASD, Amount of blood coming to RA is more d/t shunt from LA to RA.

↓

RV will take more time to empty blood into pulmonary circulation.

L/t – delayed P_2.

Although amount of blood going to LV is Less because of shunt from LA to RA

↓

So, Less blood allow LV to empty faster that L/t – Early A_2.

⊛ In VSD, Shunt is from LV to RV.

↓

So, LV empty faster d/t less blood vol. & RV empty later d/t more blood vol.

Telegram - @Latestpgnotes

↓

Results in earlier A_2 & delayed P_2.

⊆ L/t - wide Split A_2-P_2.

⊛ In MR, Some amount of blood went back to LA from LV.

↓

So, Less vol. of blood in LV ⊆ takes less time to empty.

↓

Resulting in - A_2 occur earlier.

L/t - wide split A_2-P_2.

⊛ In RBBB, RV recieves the current late.

↓

RV empties the blood late.

↓

L/t - delayed P_2.

⊛ In pulmonary stenosis, RV takes more time to get empty d/t stenosed valves

↓

L/t - delayed P_2.

Telegram - @Latestpgnotes

⊛ REVERSED SPLIT

- LV outflow obstruction like Aortic Stenosis
- LBBB
- RV pacing
- Ductus arteriosus.
- Type-B WPW Syndrome.
- Systemic HTN.

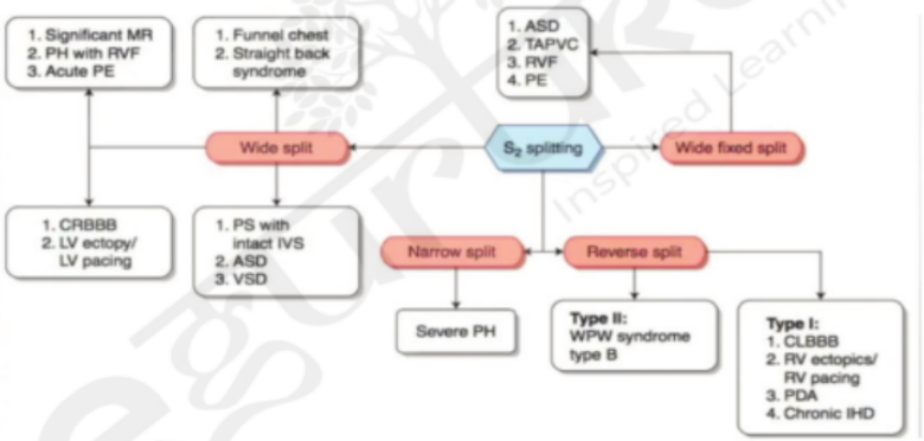

Telegram - @Latestpgnotes

HEART SOUND - S_3, S_4

- S_3 & S_4 both are ——.
  - Low pitched sound.
  - Better heard @ bell
  - Diastolic sound.

S_3	vs.	S_4
- Seems to occur where Preload is more.		- Seems to occur where afterload is more.
- Coincides @ early diastolic filling.		- Coincide @ atrial contraction.
- Physiological		- Pathological. (Except → Elderly people >60 yrs. age).
- S_3 absent on → Mitral Stenosis.		- S_4 absent on → Atrial fibrillation.

✱ MECHANISM OF S_3

- Rapid filling of ventricle → Suddenly fibres are locked into space as Ventricle can't expand further & generate vibration → Lt S_3.

Telegram - @Latestpgnotes

- All high volume overload conditions, S_3 can occur. Eg. — In Aortic Regurgitation,
  Mitral Regurgitation,
  Hyperdynamic Circulation.
- S_3 Physiological in → Children.
  Young adults.
  (Upto 40 yrs in Ⓜ)
  (Upto 50 yrs in Ⓕ).
  Pregnancy.
- Other pathological Causes of S_3 —
  - Heart failure.
  - Hyperkinetic Circulatory Status
    for eg. — Thyrotoxicosis
    Anaemia.
  - Tricuspid regurgitation
  - Ventricular Septal Defect.
  - PDA
  - TAPVD.
  - Truncus Arteriosus.
  - IHD.

Telegram - @Latestpgnotes

- Dilated Cardiomyopathy.

✱ MECHANISM OF S_4

D/t stiff ventricles → Passive filling of ventricle ↓ed → Now atria has to contract more to push blood from atria to ventricle.

↓

When atria pushes the blood into ventricle, the ventricle recieves the blood & stretches the fibre that generate vibration & cause S_4 formation.

- Pathological Causes of S_4 —
  - Acute MR
  - Acute AR
  - LVOT obstruction i.e AS., HTN.
  - RVOT obstruction i.e PS, Pul. HTN.
  - IHD
  - Heart blocks.

✱ LV - S_3 vs. RV - S_3

Telegram - @Latestpgnotes

• Site → Apex.	• Site → Lt. LSB.
• Heard best during expiration.	• Heard best during inspiration.
• Best auscultated at Lt. Lat. position.	• Best auscultated at supine position & Passive leg raising.
• Isometric Hand grip → LV-S_3 ↑	• Isometric Hand grip → RV-S_3 (No change).
• Associated findings → MR, AR	• Associated findings → Raised JVP.

⊛ EJECTION CLICK

- It is a clicking sound occur in a damaged valve.
- Typically occur in — Aortic Stenosis & Pulmonary Stenosis. When valve pathology ⊕.
- Pulmonary EC ⇒
  - Varies ε respiration.
  - Soft in inspiration & loud in expiration

Telegram - @Latestpgnotes

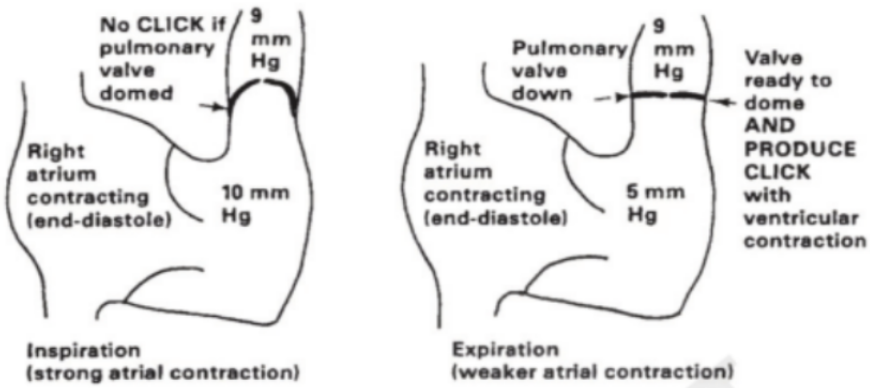

✳ Opening Snap

- High pitched sound, Heard all over the precordium.
- Opening of mitral valve (damaged) causes opening snap sound.
- S_2 - OS gap less → ↑ed length of murmur.

  S_2 - OS gap more → ↓ed length of murmur.

  → Indicates → Severe MS.

Telegram - @Latestpgnotes

HEART MURMURS - 1

✱ WAVEFORMS 00:30

Understanding the waveforms

- A-Wave → Atrial Contraction.
- C-wave → Mitral valve closure.
- X-descent → Atrial relaxation & annular descent.
- V-wave → Atrial filling.
- Y-descent → Atrial emptying.

✱ Analogous right-sided waveforms at lower absolute pressures.

✱ CARDIAC CYCLE

Telegram - @Latestpgnotes

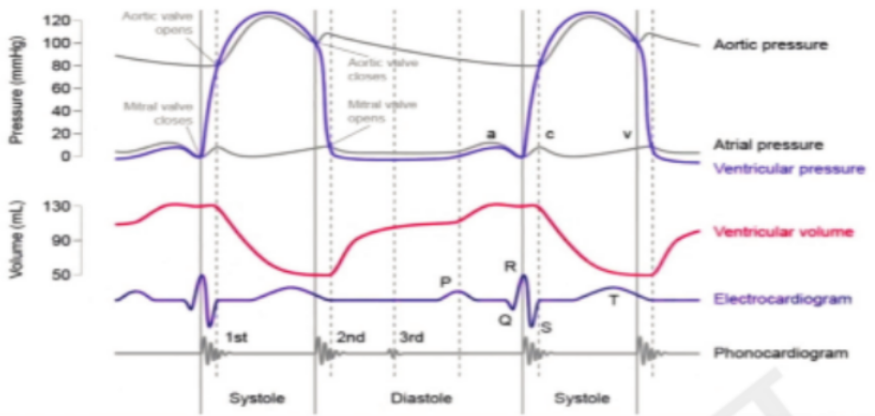

✱ MURMURS

- 3 main reasons to generate murmur —

  (I) Ted Blood flow → passing through

  Ⓝ an Ab-Ⓝ orifice.

  (II) Blood flow from narrowed orifice to dilated chambers.

  (III) Backflow through an incompetent valve.

- For a murmur to occur, there should be —

  Turbulent Blood flow.

  ↓

Telegram - @Latestpgnotes

- Generally occurs when reynolds number > 2000.

It means → High Blood flow velocity or Low kinetic viscosity.

- Orifice through ε blood are passing should be small.
- ↓ kinetic viscosity.

⊛ VORTEX SHEDDING & PERIODIC WAKE PHENOMENA



⊛ CLASSIFICATION OF MURMURS

Murmurs
- Systolic
- Diastolic.

Telegram - @Latestpgnotes

Systolic murmur.

- Ejection Systolic murmur. (ESM).
  - ↓
  - Forward flow of blood from LV/RV into the outflow tract.
- Regurgitant murmur.
  - ↓
  - Retrograde flow from high pressure cardiac chamber to a low pressure chamber.

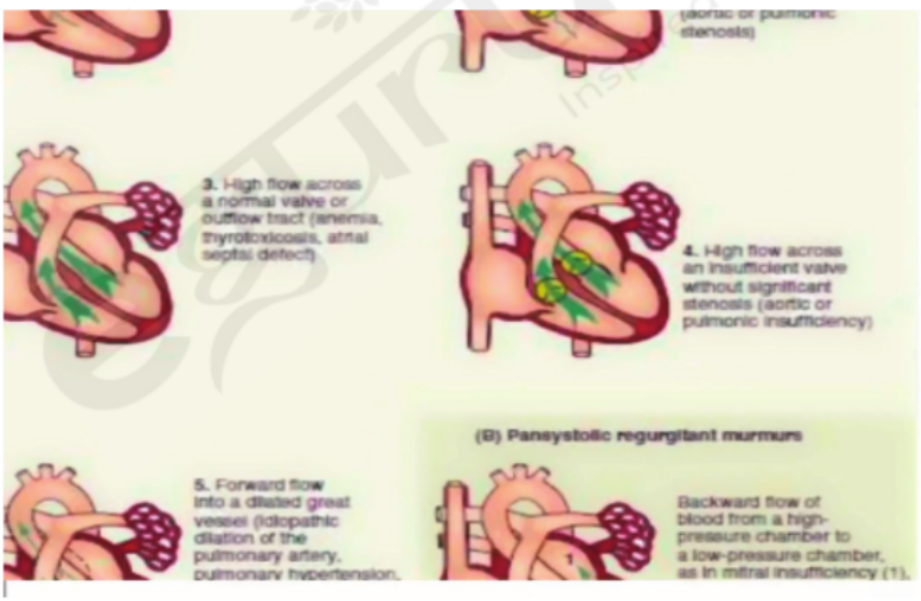

Telegram - @Latestpgnotes

⊛ AREAS OF AUSCULTATION

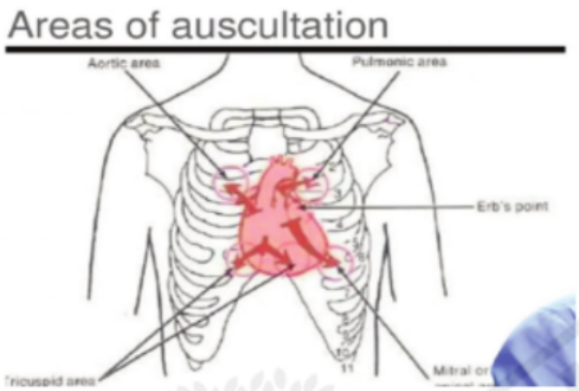

- Aortic Area → 2nd ICS, Rt. Side parasternum.
- Pulmonary Area → 2nd ICS, Lt. Side parasternum
- Tricuspid Area → 4th ICS, Lt. Lower Sternal border.
- Mitral Area → Apex of Heart. (Midclavicular Line, 5th ICS)
- Erb's Point → 3rd Lt. ICS.

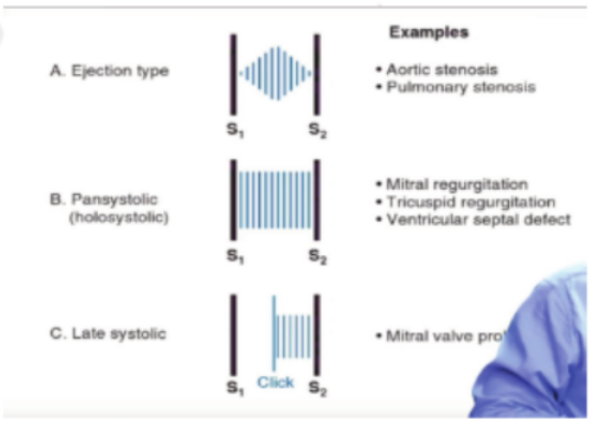

Telegram - @Latestpgnotes

✱ Ejection Systolic Murmur

- They are — Diamond Shaped.
- Seen in → Aortic Stenosis
  Pulmonary Stenosis.

✱ Pansystolic Murmur

- Seen in → Mitral regurgitation
  Tricuspid regurgitation.
  VSD.

✱ Late Systolic Murmur

- Seen in → Mitral Valve Prolapse
  ↓
  Associated w — Midsystolic Click.

✱ Systolic Murmurs

(I) Early Systolic Murmur →

- Seen in — Acute MR.
  VSD → Muscular VSD
  → Non restricted VSD w
  Aw. HTN.

Telegram - @Latestpgnotes

TR (↓ ⓝ pul. artery pressure).

(II) Midsystolic Murmurs →

• Seen in — (A) Aortic Outflow problem.

- Obstructive.
  - ↳ Supravalvular AS
    Coarctation of aorta
    Valvular AS
    Aortic sclerosis
    Subvalvular HOCM.
- ↑ed flow (Flow murmurs)
  - ↳ Hyperkinetic State.
    (Thyrotoxicosis, Anaemia)
    Aortic regurgitation.
- Dilation of ascending aorta.

(B) Pulmonary Outflow problem.

- Obstructive
  - ↳ Supravalvular pul. artery Stenosis.
    Valvular PS.

Telegram - @Latestpgnotes

Subvalvular Infundibular Stenosis.

- ↑ed Flow.
  - ↳ Hyperkinetic State.
    ASD (L→R Shunt).
- Dilation of pulmonary artery.

(III) Late Systolic Murmurs →

- Seen in → MVP.
  Acute MI ∵ papillary m. rupture.
  Tricuspid valve Prolapse.

✱ DIASTOLIC MURMUR

Classification based on physiologic mechanism of production

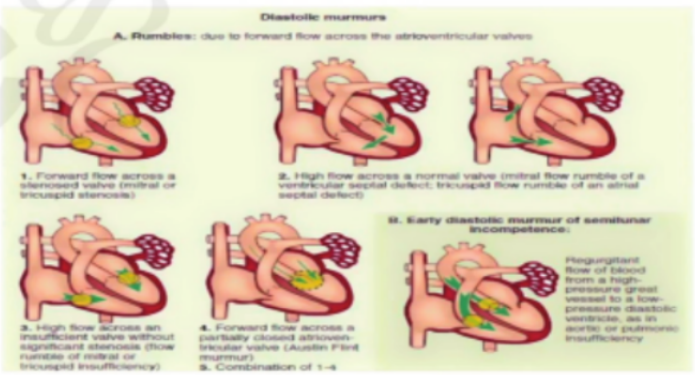

Telegram - @Latestpgnotes

- Early Decrescendo Murmur ⇒
  - Seen in → Aortic Regurgitation
    Pulmonary Regurgitation.

- Mid to Late Diastolic Murmur ⇒
  - Seen in → Mild MS or TS.

- Prolonged Mid to Late Diastolic murmur ⇒
  - Seen in → Severe MS or TS.

⊛ Early Diastolic Murmur ⇒

- Aortic Regurgitation → Valvular
  → Dilation of valve anulus.
  ↓
  Occur d/t - Dissection of aorta.

  ↓
  Widening of Commissures.
  ↓
  Occur d/t Syphillis.

- Pulmonary Regurgitation.
  - Valvular (Endocarditis, Rheumatic, Carcinoid)
  - Dilating Anulus (Pul. HTN, Marfan)
  - Congenital defects.

Telegram - @Latestpgnotes

✱ MID DIASTOLIC MURMUR.

- Mitral valve diseases.
  - MS.
  - Carey Coomb's Murmur → Acute Rheumatic fever.
  - Ted flow.
    - ↳ MR, VSD, PDA, High output states.
- Tricuspid valve diseases.
  - TS.
  - Ted flow
    - ↳ TR, ASD, TAPVR/PAPVR.
- Rt. or Lt. atrial tumors (myxomas).
- Severe - AR. (Austin flint murmur).

✱ LATE DIASTOLIC MURMUR

- Presystolic accentuation of —
  - Mitral Stenosis murmur.

✱ CONTINUOUS MURMUR

Telegram - @Latestpgnotes

• Occur in both systole as well as diastole.

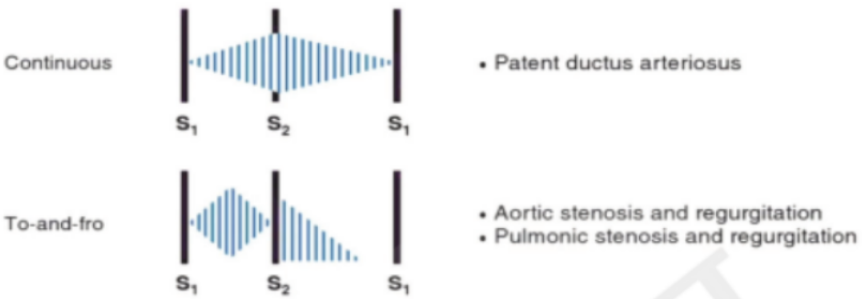

⊛ To & FRO Murmur

• Occur in both systole as well as diastole.

• Seen in ⟶ AS & AR.
PS & PR.

⊛ Continuous murmur seen in —.

(I) PDA
(II) Coronary A-V fistula
(III) Ruptured sinus of valsalva aneurysm
(IV) ASD.
(V) Cervical venous hump.
(VI) Anomalous Lt. Coronary art.

Telegram - @Latestpgnotes

(VII) Proximal coronary art. stenosis.

(VIII) Mammary shuffle in pregnancy

(IX) Peripheral pulmonary art. stenosis

(X) Small ASD & MS

(XI) Intercostal AV fistulas.

⊛ LOCALIZATION OF MURMURS

Murmurs at the apex

ONLY AT APEX	BEST HEARD SOMEWHERE ELSE BUT ALSO HEARD AT APEX	NOT HEARD AT APEX
Systolic murmur of MR	ESM of AS	Murmurs of right sided origin (but can be heard when RV forms the apex
ESM of calcified AS in elderly patients with emphysema (loss of jet effect)	Pansystolic murmur of TR, VSD	ESM of PS
MDM of MS	MDM of TS	EDM of PR
Functional MDM of MR		

Gallavardin's Phenomena =>

- Some component of AS murmur heard at the apex.

Murmurs at tricuspid area

AT TRICUSPID AREA ONLY	BEST HEARD SOMEWHERE ELSE BUT ALSO HEARD AT TRICUSPID AREA	NOT HEARD AT TRICUSPID AREA
Systolic murmur of TR	PSM of MR and VSD	MDM of MS
MDM of TS	ESM of AS and PS	

Telegram - @Latestpgnotes

Murmurs at left sternal border of 3rd intercostal space

ONLY AT LSB	BEST HEARD ELSEWHERE BUT ALSO ALONG LSB	NEVER HEARD
PSM of VSD	**ESM of valvular PS,and TR**	MDM of MS
ESM of infundibular PS		
EDM of AR		

Murmurs at Pulmonary area

BEST HEARD	BEST HEARD ELSEWHERE BUT ALSO ALONG PA	NEVER HEARD
ESM of PS	AS	MDM of MS and TS
Flow murmur of pulmonary origin in ASD	VSD	
Continuous murmur of PDA	MR,AR	
Murmur of sub pulmonary VSD		

Murmurs at Aortic area

BEST HEARD	RARELY HEARD: ESM of PS
ESM of AS(valvular, subvalvular), aortic sclerosis	Never heard : MDM OF MS
EDM of AR	

⊛ CHARACTERISTIC OF MURMUR

- Timing of murmur

Telegram - @Latestpgnotes

- Location ⟶ Radiation.
- Shape
- Pitch.
- Intensity.
- Quality
- Response to manouvrie's.

✱ Duration of Murmur ⟶

(I) Regurgitant (MR, TR, VSD) systolic murmurs are usually longer than stenotic lesions.

(II) Sometimes the length of murmur can tell about severity of diseases.

✱ FACTORS THAT INFLUENCE MURMUR INTENSITY ⟶

(I) Amount of blood flow through lesion zone.

Eg.→ Rt. heart murmurs are louder in inspiration.

Lt. heart murmurs are louder in expiration.

(II) Size of Orifices.

(III) Chest wall thickness.

Telegram - @Latestpgnotes

- Obesity, Emphysema → Low intensity of murmur.

- Thin chest wall → High intensity of murmur.

✳ Character & frequency of murmur is directly proportional to velocity of blood flow.

- High Pressure gradient → High pitched murmur.

- Low pressure gradient → Low pitched murmur.
  ↓
  More Rough & Rumbling in nature

- Mix frequency murmurs are seen in →
  - VSD
  - PS
  - AS.

✳ TRANSMISSION OF MURMUR

- AS murmur → goes to Carotids.
- Pansystolic murmur → goes to – Axilla & Back.

Telegram - @Latestpgnotes

7. HEART MURMURS - 2

- Aortic Stenosis.

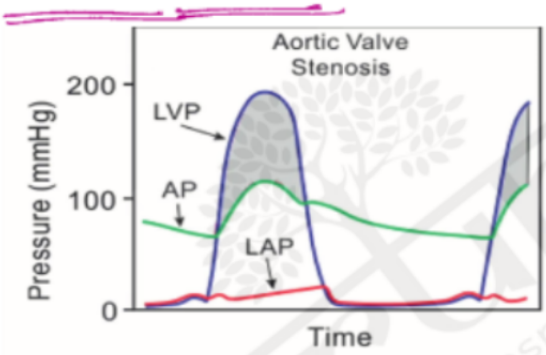

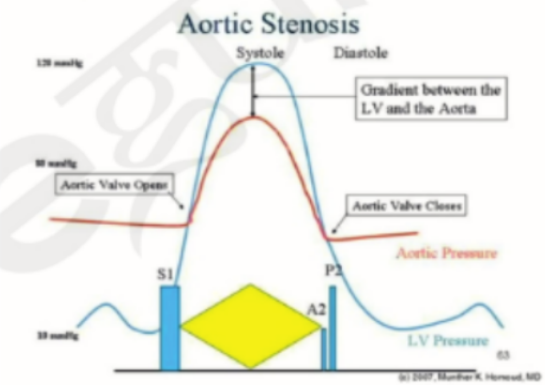

Telegram - @Latestpgnotes

Aortic Stenosis

→ Crescendo - Decrescendo.

Diamond Shape Murmur

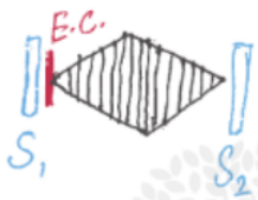

→ Low volume Slow rising Pulse

:- Pulsus Parvus Ectasdus.

→ ↓ SBP.

→ LVH

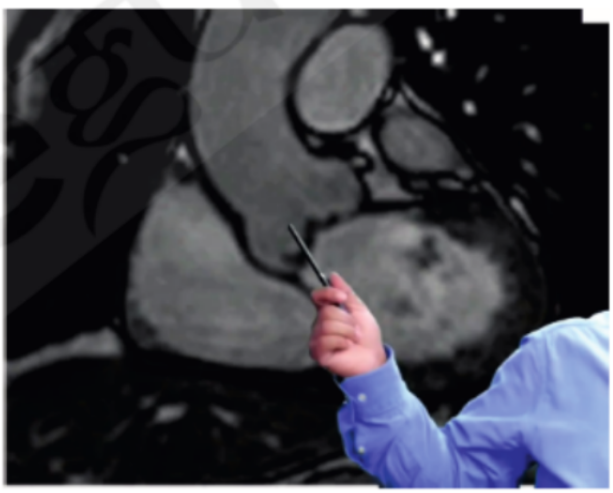

Telegram - @Latestpgnotes

↳ LVH.

Symptoms → SAD.

- Angina
- Syncope.
- Dyspnea.

- Sustained LV. Impulse.
- S_4 - Diastolic
- Ejection Click : If Valvular Pathology.

If Murmur Best Heard at →

→ (R) 2nd Intercostal Space
↳ Conducted to → Carotids
- Valvular - Non Calcific A.S.
- Bicuspid (A.S.).

→ Left Sternal Border → Subvalvular A.S.
No Conduction → Calcific A.S.

→ Carotid Murmer. + 2nd I.C.S W/Absent. → Supravalvular A.S. (Elfen Facies).

Telegram - @Latestpgnotes

If Murmur Audible ⟶ Apex.

Gallaverden's

↓

Calcific A.S.

Elderly ∈ Emphysema

(Not radiated to Axilla)

| Radiates to Axilla in M.R |.

(A) Mild.



Early Peaking.

(B) Moderate.

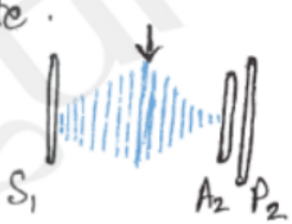

(C) Severe

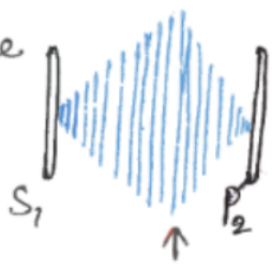

Late Peak.

A_2 becomes Soft.

Telegram - @Latestpgnotes

Gallavardin Phenomena.

→ Elderly patient with Aortic Stenosis/Sclerosis due to fibro Calcific Changes have Gallavardin dissociation.

Two distinct Murmurs Heard-

- A noisy pitched murmur at the right Second Space (Due to Turbulence Caused by the High Velocity Jet within Aortic root).
- A High frequency Musical Murmur at the Apex (Due to Periodic wake Phenomenon Caused by High frequency Vibrations to the fibrocalcific Aortic Cusps)

→ Simulates Murmur of M.R. but Without radiation to back or Axilla or is Accentuated with slowing of Heart rate Such as a Compensatory pause or premature Beat.

— Pulmonary Stenosis.

- Valvular P.S.

Best Heard :- left 2nd – 3rd I.C.S.

Telegram - @Latestpgnotes

- Conducted to left Supraclavicular & (+) Side of Neck.
- left 2nd – 3rd I.C.S.

- Begins ≅ a E.C. (Valvular).

↑ → Expiration.

Absent → Inspiration

(Only (Rt) Heart Sound that ↑ on expiration,
generally most (Rt) Heart Sound ↑ on Inspiration)

- S_4 – Rt side (+)
- P_2 – Soft
  - S_2 :- Wide Split.
- JVP – 'a' waves (+)
  - left Parasternal Heave :- RVH

RV – S_4 → ↑ on Inspiration.

- Ejection Systolic Murmur (ESM).
  - ↑ on Inspiration
  - ↓ on Valsalva / Standing.

Same tnt in A.S.

Telegram - @Latestpgnotes

(20:58) Vulvular Pulmonic Stenosis.

- late Peaking
- longer Murmur } Severe
- P_2 is Soft / Absent

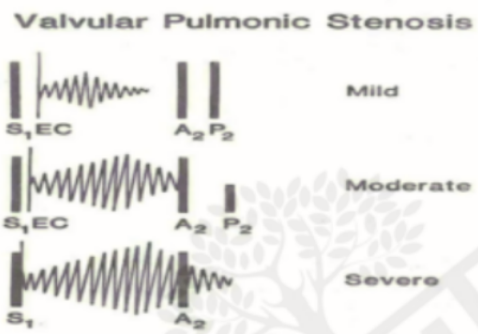

Subvalvular P.S :- Infundibular P.S.

→ Assot. ⊂ TOF

- Best Heard :- 3rd I.C.S.
- Murmur :- becomes Shorter with Increased Severity.
- P_2 - Absent.

Mild TOF :- Late Peaking.

Mod. TOF :- Early Peaking

Severe TOF :- Small murmur / Almost Absent

Telegram - @Latestpgnotes

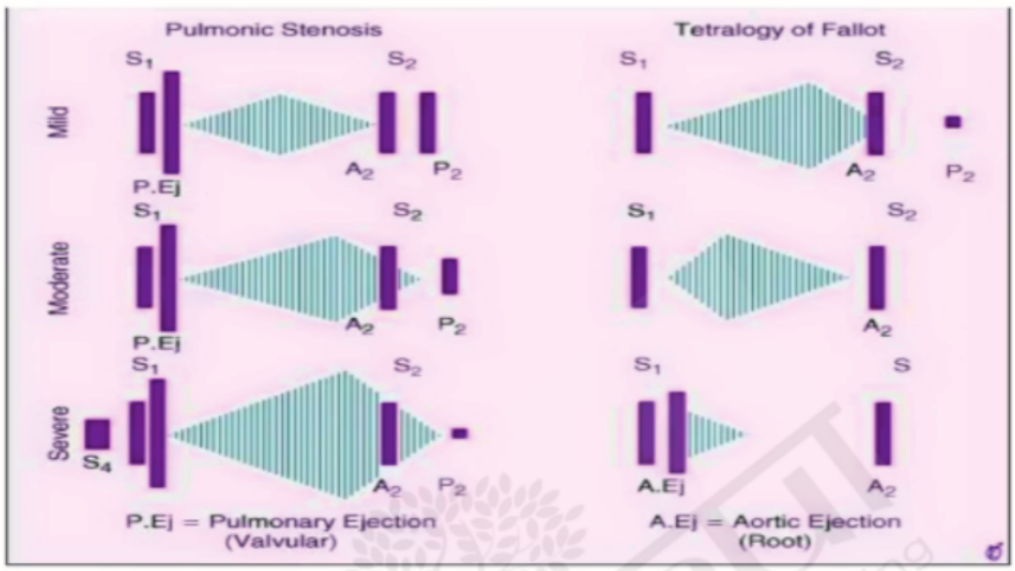

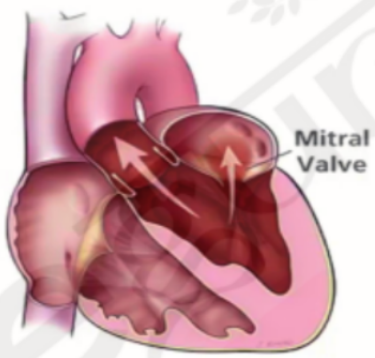

Mitral Regurgitation → Throughout Systole L.V. Pressure dominates over L.A. Pressure which Creates Murmer (Pansystolic)

Telegram - @Latestpgnotes

Acute M.R:- Early Systolic Murmer

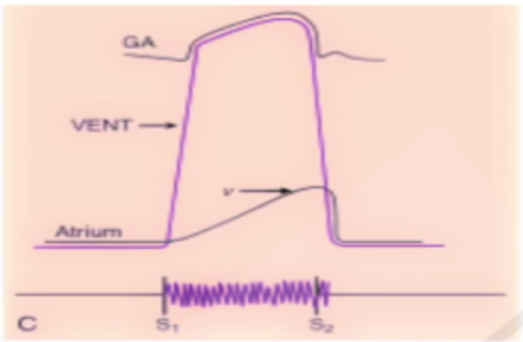

FIGURE 10.9 A, Phonocardiogram (top) obtained in a patient with acute severe mitral regurgitation (MR) showing a decrescendo early systolic murmur (SM) and diastolic filling sound (S_3). **B,** Left ventricular (LV) and left atrial (LA) pressure waveforms demonstrating the abrupt rise in LA pressure and attenuation of the LV-LA pressure gradient, resulting in the duration and configuration of the SM. **C,** Illustration of great artery (GA) and ventricular (*VENT*) and atrial pressures with corresponding phonocardiogram in chronic MR or TR. Note the holosystolic timing and plateau configuration of the murmur, both of which derive from the large ventricular-atrial pressure gradient throughout systole; *v* wave. (From Braunwald E, Perloff JK. Physical examination of the heart and circulation. In Zipes D, Libby P, Bonow RO, Braunwald E, editors. Braunwald's Heart Disease: a Textbook of Cardiovascular Medicine. 7th ed. Philadelphia: Saunders; 2005. p 97.)

Pansystolic

Diastolic
S_3 (+)

Pansystolic Murmer : M.R.

- High Pitched
- Blowing quality.
- Begins @ S_1 continues → S_2

Rule out T.R. & VSD

Telegram - @Latestpgnotes

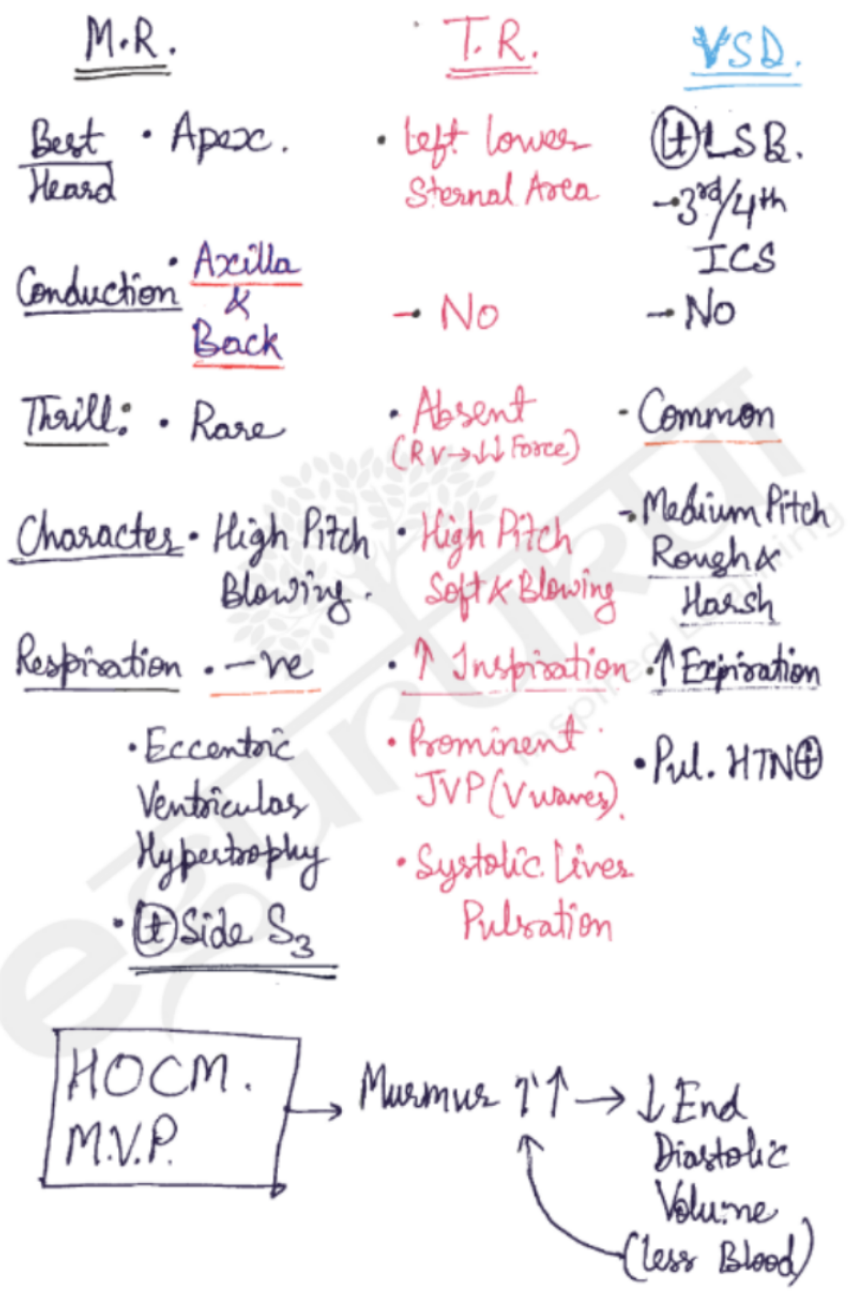

Telegram - @Latestpgnotes

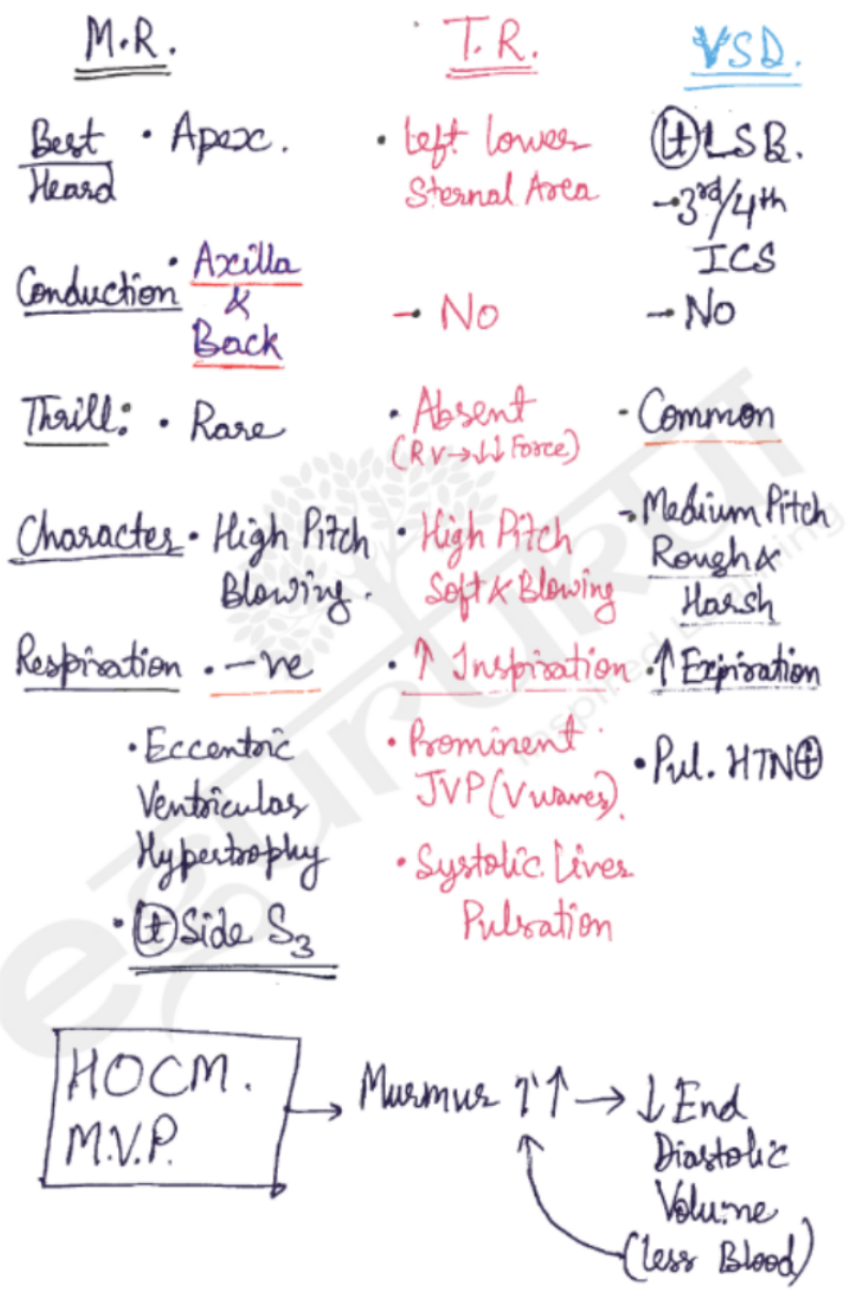

Telegram - @Latestpgnotes

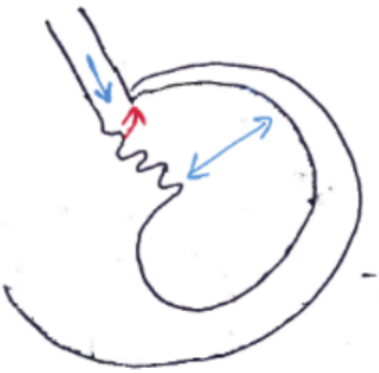

LV → Problem in Septum

- With less Blood Septum Obstructs.

HOCM.

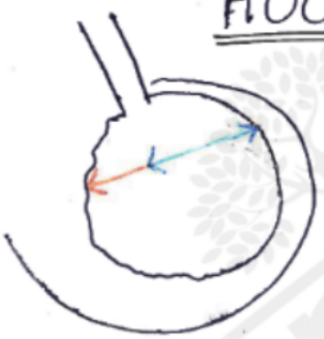

- With More Blood. Septum Rushed Away.

More Blood → ↓ Murmur

less Blood → More Murmur

Mitral Valve Prolapse.

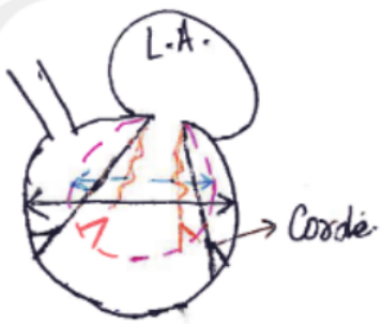

Telegram - @Latestpgnotes

less Blood → Faster Prolapse → longer Murmur.

More Blood → Empty out Partly in Aorta. → Shorter Duration Murmur

(Walls of Ventricle become closer than only Chorda become lapse enough to allow Prolapse

(standing) ↓ EDV → longer Murmur.

↑ EDV → Shorter Murmur.

(lying)

Dynamic Ascultation Most Useful → MVP & HOCM

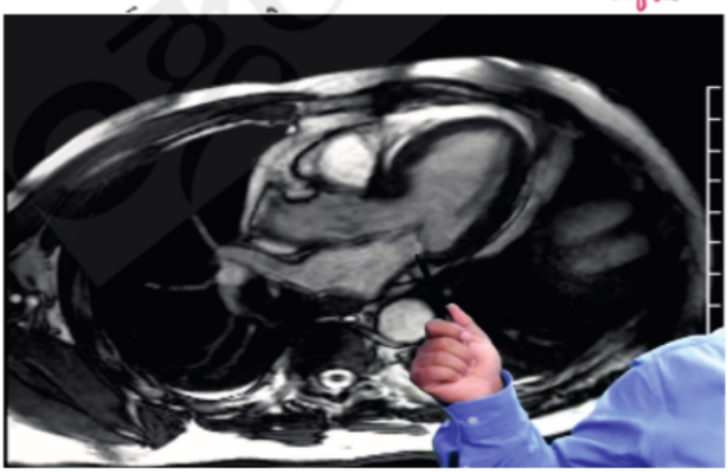

Telegram - @Latestpgnotes

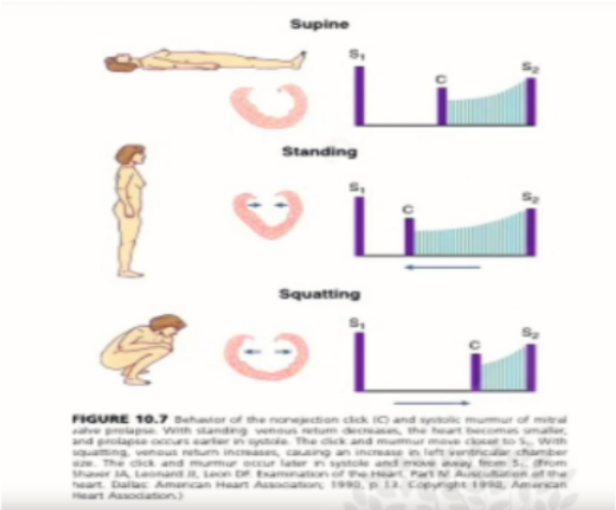

FIGURE 10.7 Behavior of the nonejection click (C) and systolic murmur of mitral valve prolapse. With standing, venous return decreases, the heart becomes smaller, and prolapse occurs earlier in systole. The click and murmur move closer to S_1. With squatting, venous return increases, causing an increase in left ventricular chamber size. The click and murmur occur later in systole and move away from S_1. (From Shaver JA, Leonard JJ, Leon DF. Examination of the Heart. Part IV. Auscultation of the heart. Dallas: American Heart Association; 1990. p. 13. Copyright 1990, American Heart Association.)

(43:42) MVP - MRI

MVP

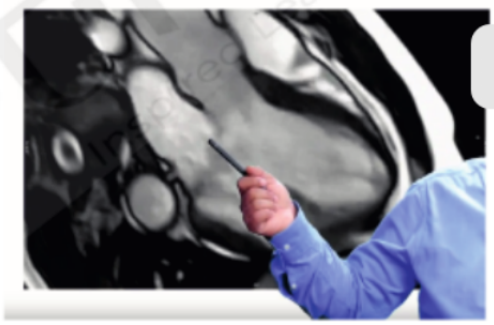

Manovers	Effect	Murmer. Hcom	MVP	A.S.	M.R.
– Valsalva/ Standing.	↓ Return to LV	↑	↑	↓	↓
– Supine/Squatting leg Raising.	↑ Venous Return	↓	↓	↑	↑

Telegram - @Latestpgnotes

Manoeuvres	Effect	HOCM	MVP	A.S.	M.R
– Hand Grip	↑ After load	↓	↓	↓	↑
– Phenylephrine (↑ Resistance in Aorta (↑ Pressure)					
– Nitrates (Veno-Dilator)	↓ After load	↑	↑	↑	↓
– Post Premature Ventricular (PVC) Contraction	↓ Afterload ↑ Volume	↑ =	↓ =	↑	↓

More Volume
More Diameter
less Murmur

Diastolic Murmurs

– Early Diastolic Murmurs : Regurgitant.
↓
A.R., M.R.

– Mid Diastolic Murmurs :
Late Diastolic Murmurs :
Obstruction in Foward Flow across AV-Valves

Telegram - @Latestpgnotes

– M.S, T.S.

Early Diastolic Murmurs.

– Start S_2



– High Pitch : Reflect High Velocity of Regurgitant Blood → from Great Vessels.

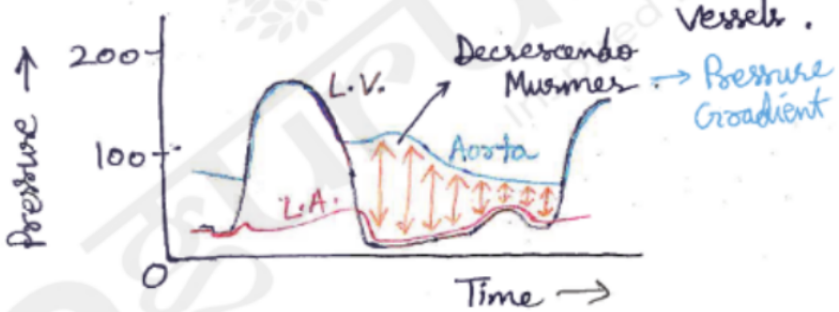

- Shape(decrescendo) & length(short) of EDM reflects diastolic pressure gradient between aorta or pulmonary artery & respective ventricles

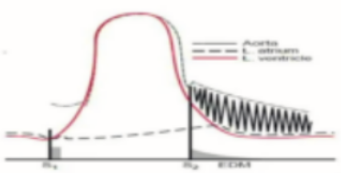

Relationship of early diastolic murmur (EDM) to hemodynamics in aortic regurgitation—EDM is due to diastolic pressure gradient.

Telegram - @Latestpgnotes

Common Cause

(early) EDM :- • A.R.

• Functional P.R.

(Graham Steel Murmer).

↳ No Valve Disease but occurs due to Pulmonary HTN.

- Decrescendo.
- Soft-High Pitch - Blowing in character
- "Cooing Dove" → Musical Diastolic Murmur.

↓ Endocarditis → ↓ Rupture / Retroversion of Aortic Cusp.

EDM → A.R.

→ Best - Heared :- Sitting / leaning Forward

→ Expiration.

→ LSB → 3rd / 4th I.C.S.

If Aortic Root # → A.R: (R) 2nd I.C.S.

Telegram - @Latestpgnotes

Hand Grip → ↑ After load.
A.R. → ↑ EDM.
↑ Murmur.
Nitrates → ↓ Murmur

A.R.

- Carotid Pulse (Dancing Pulse)
  - Rapid Rise → large Volume.
- A.R. (Valvular)
  - A_2: Soft/Absent

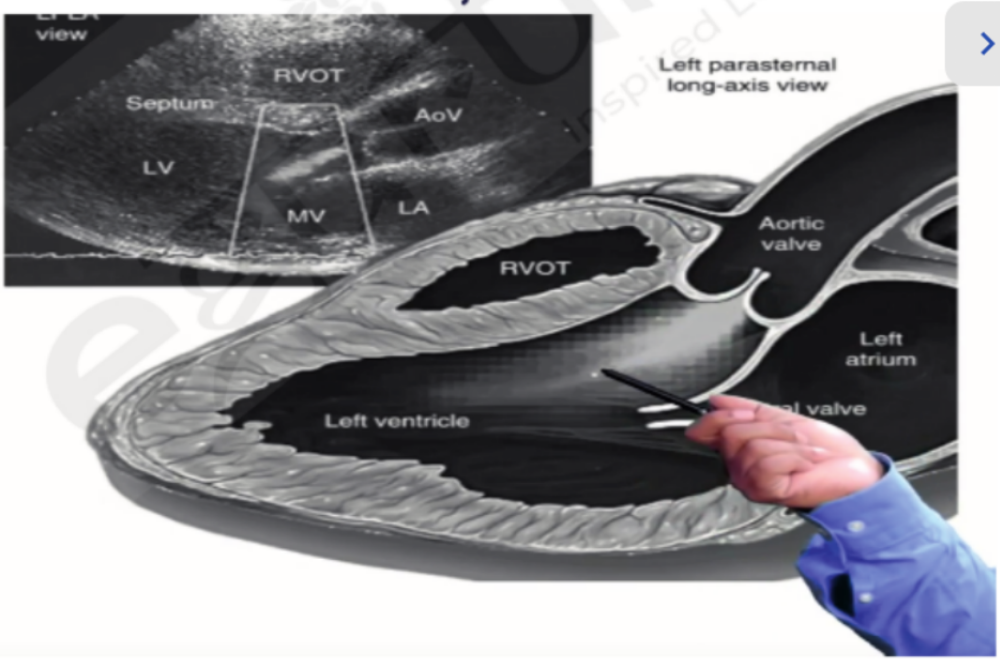

Telegram - @Latestpgnotes

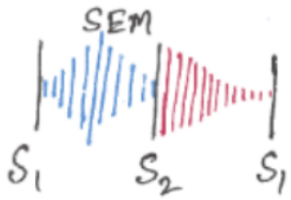

Chronic .

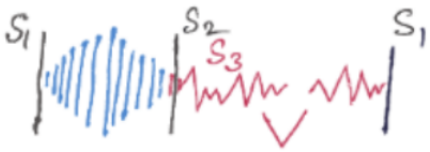

A.F.

Apex
- Austin Flint Murmur

Mitral Area
- S_3

Acute
↓
Not Audible
↓
L.V. wont recieve blood that its not used to.

MID Diastolic Murmurs

- Fooward flow : AV-Valves .
- low Pitched & Rumbling . (M.S.).
  Atrium doesnt have enough Pressure to Push Blood in Ventricle .
- Calcified Immobile valve .
  → High frequency → Murmur .
  low Intensity / No thrill

Calcified M S less common (More Common c [Aortic Valve]

Telegram - @Latestpgnotes

Severity → Mitral Stenosis.

- Length of Murmur (↑ length → ↑ Severity)
- Intensity → Poor Correlation ∝ Severity

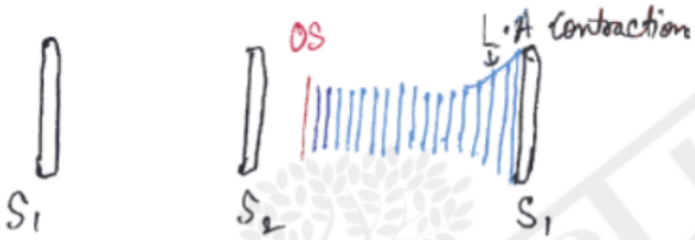

↑ Stenosis : ↑ L.A Pressure : (Valve opens Fast) Faster Blood Ejection

↓

Early O.S.

Mid. M.S. → ↓ length.

Telegram - @Latestpgnotes

Severity → Mitral Stenosis.

- Length of Murmur (↑ length → ↑ Severity)
- Intensity → Poor Correlation ∝ Severity

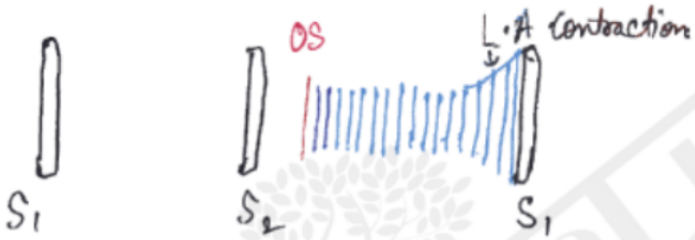

↑ Stenosis : ↑ L.A Pressure : (Valve opens Fast) Faster Blood Ejection

↓

Early O.S.

Mid. M.S. → ↓ length.

Telegram - @Latestpgnotes

- ↑length → Murmur → ↑M.S.
- ☆ S_2 – O.S. gap ·Shorter → ↑ Severity M.S.

– Presystolic Accentuation due to Atrial Kick
☆ └→ Not Present in Atrial Fibrillation.

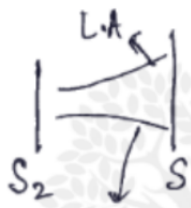

Atrium required for Accentuation

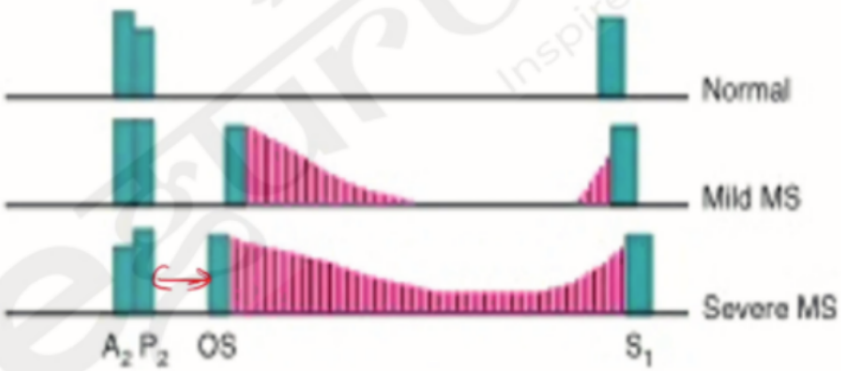

S_1 Intensity → Varies in Patients with – MS ∈ Atrial Fibrillation.

length of Murmur → Also Varies

Telegram - @Latestpgnotes

CONGENITAL HEART DISEASE - 1

- **Cyanotic**
  - Pulm BF ↓
    - TOF
    - Ebstein's anamoly
    - Tricuspid atresia
  - Pulm BF ↑
    - TAPVC
    - TGA
    - Truncus arteriosis
- **Acyanotic**
  - VSD
  - ASD
  - PDA
  - Coarctation of aorta
  - Hypoplastic LV

Embryology :

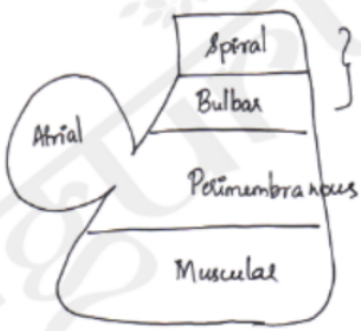

Telegram - @Latestpgnotes

Images:

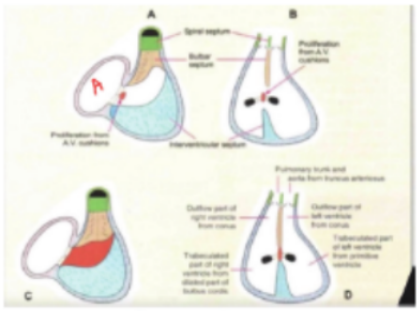

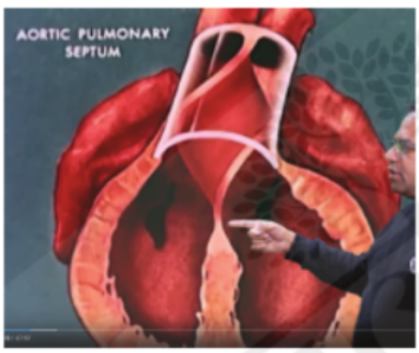

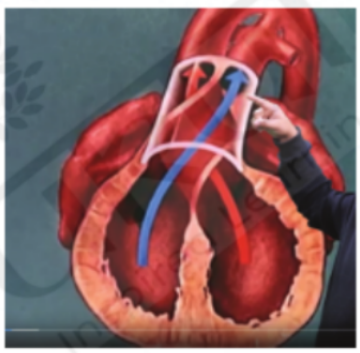

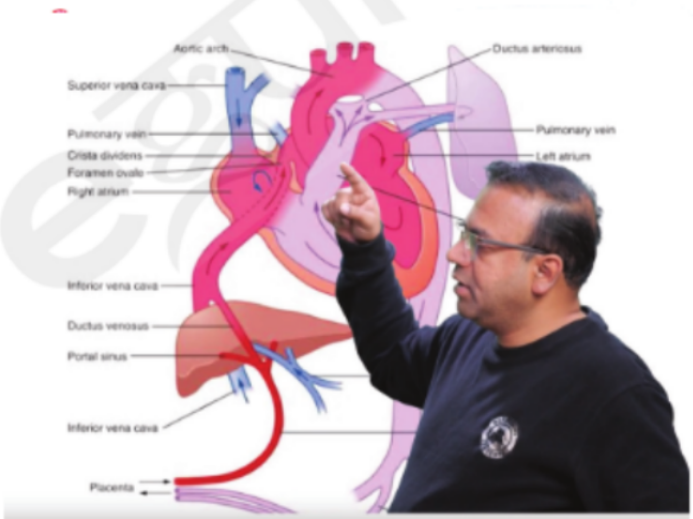

Telegram - @Latestpgnotes

Tetralogy of Fallot

- Septum spiral is displaced anteriorly.
  - ↳ Infundibular stenosis
  - ↳ Overriding of aorta
  - ↳ RVH
  - ↳ Non-restrictive VSD

Image of Fetal circulation:

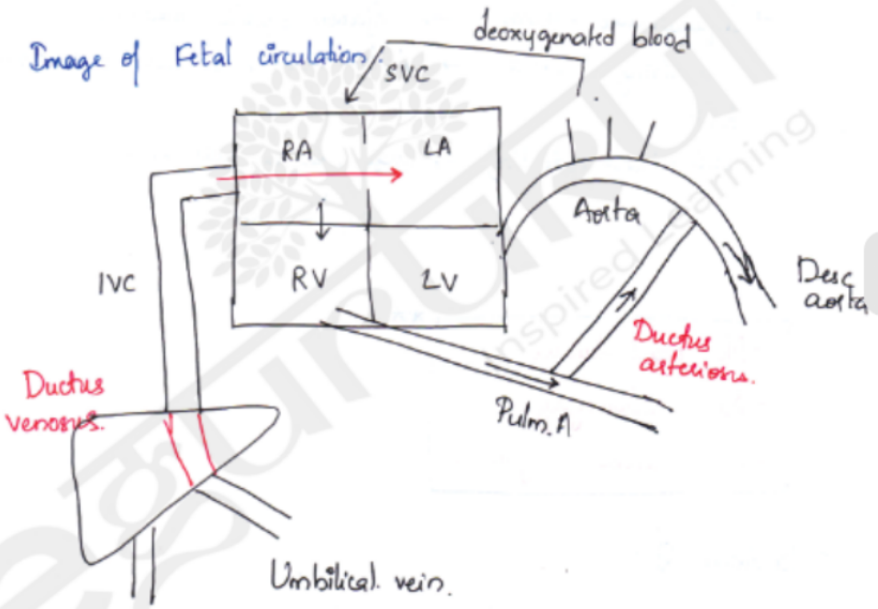

After birth:
- Umbilical V clamping → IVC pr ↓ → RA pr ↓ } Interatrial septum closes. [physiological]
- Lungs open → Venous return → LA pr ↑ }
- Patent foramen ovale - 25% of adults.

Telegram - @Latestpgnotes

★ In patients with TAPVC & Tricuspid atresia ⟹ Patent foramen ovale / ASD

TOF

- Anterior displacement of ↑ septum spirale.
  - ↳ Infundibular stenosis ⟹ Ejection systolic murmur
  - Over riding of aorta → Aorta picks blood from both RV & LV.
  - RVH
  - VSD (Non-restrictive) → large, so no turbulance → No murmur.

**
- No Heart failure
- No cardiomegaly.
- No newborn cyanosis

- Palliative ↑:
  - ↳ Blalock Taussig Thomas shunt: PA ⟷ Subclavian
  - ↳ Potts shunt: Desc aorta ⟷ (L) PA
  - ↳ Waterston's shunt: Asc aorta ⟷ (R) PA

Telegram - @Latestpgnotes

Cyanotic spell [Tet spell]

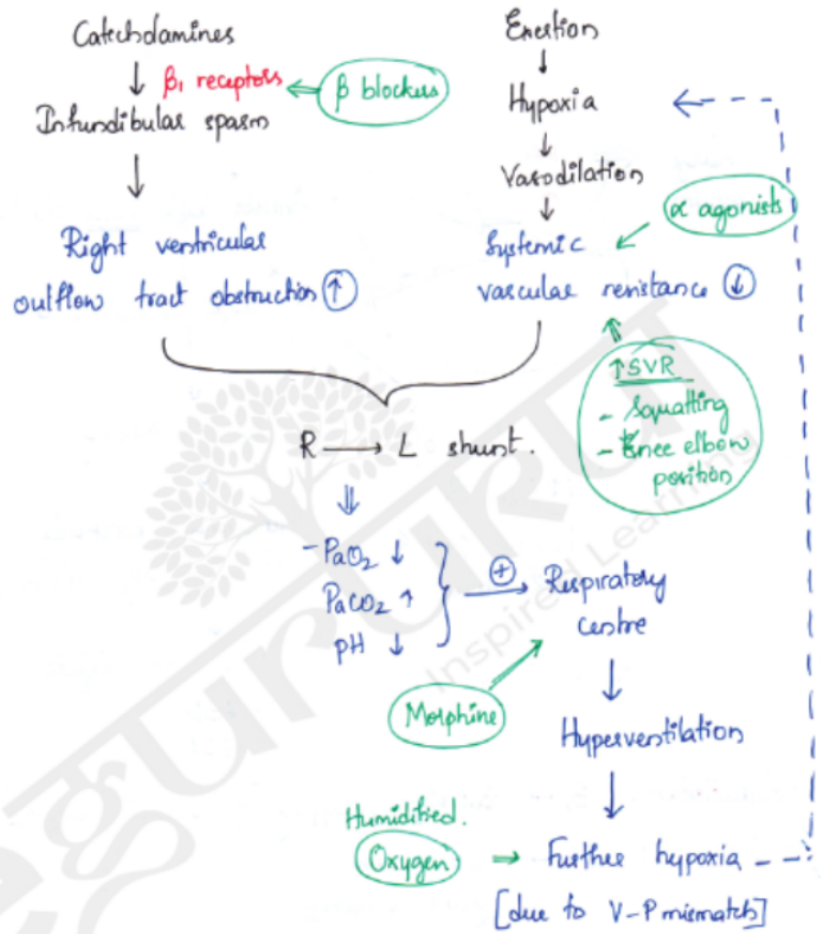

CXR: - Pulmonary oligemia

- Boot shaped heart - coeur en sabot

Telegram - @Latestpgnotes

Ebstein's anamoly - Congenital heart disease 2

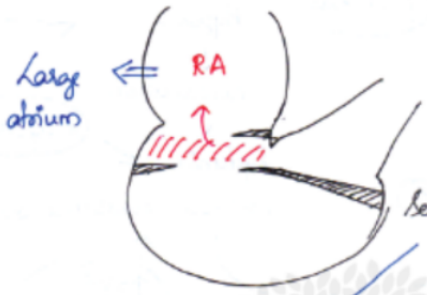

Anterior* leaflet never shifted

Septal* leaflet is shifted down

Part of (R) ventricle becomes part of (R) atrium.

Creates tethering

↓

Functional blockade of pulmonary outflow.

↓

∴ associated defects:
- ASD
- PDA

- Auscultation: S_1 → Sail sign. [flapping of tricuspid leaflet]
- JVP : TR → CV waves [giant 'v' waves]
- Xray : Box shaped heart [RA - large]
  Pulmonary oligemia
- ECG : Tall 'P' waves in lead II [Right atrial enlargement]

Telegram - @Latestpgnotes

Images :

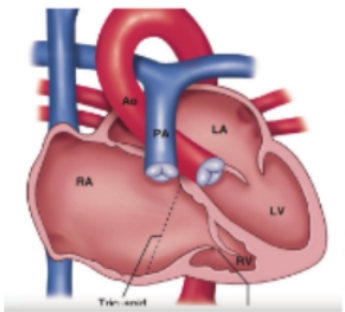

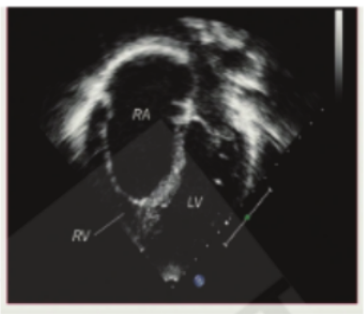

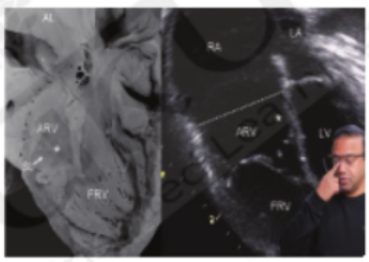

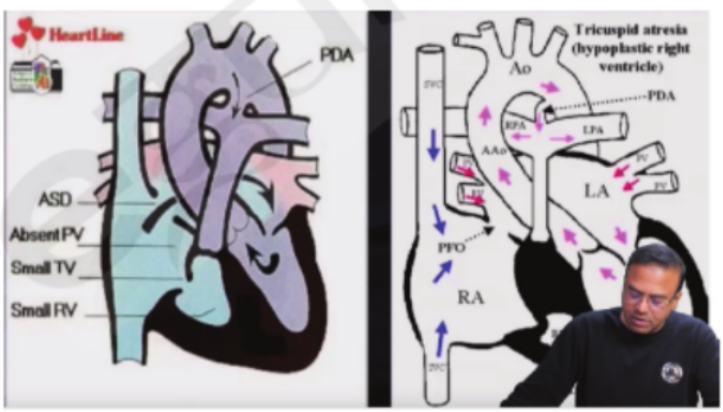

Telegram - @Latestpgnotes

Tricuspid atresia

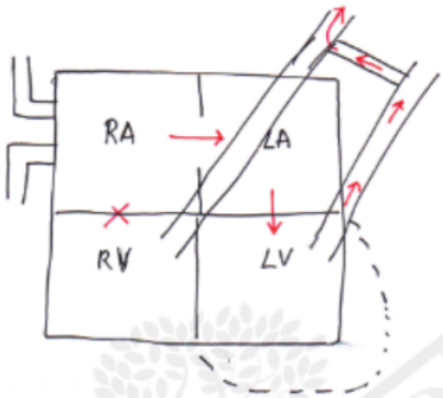

ECG → Left axis deviation*

℞ :
- Modified BT shunt
- Fontan's procedure [IVC ⟷ PA]
- Glenn's procedure [SVC ⟷ PA]

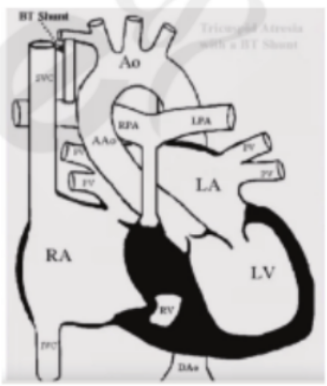

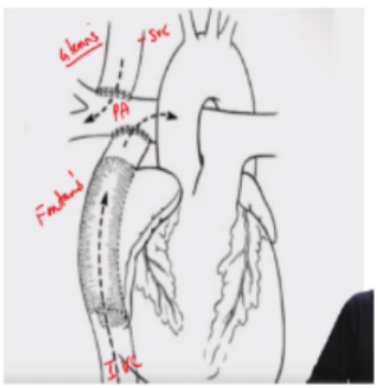

Telegram - @Latestpgnotes

TAPVC / TAPVD

M.C Supracardiac — via vertical veins / directly into SVC

- Cardiac - directly into (R) atrium at coronary sinus
- Infracardiac - into IVC or portal circulation. through diaphragmatic opening.

⇓

Worst prognosis [as ↑ risk of obstruction]

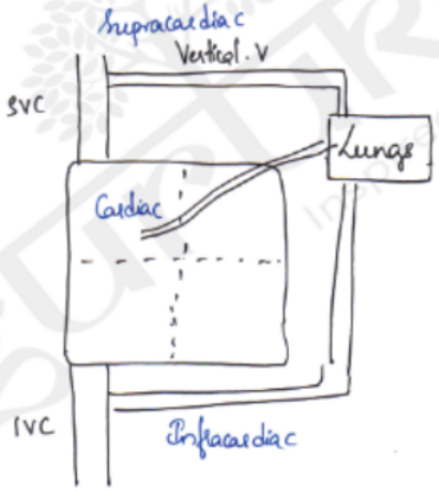

- Xray : 'Figure of 8' appearance / Snowman's appearance
  - ↑ pulmonary markings

Telegram - @Latestpgnotes

Images :

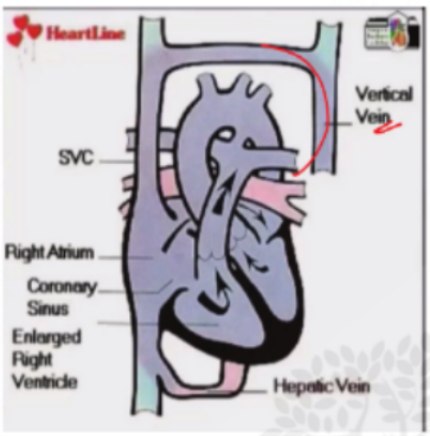

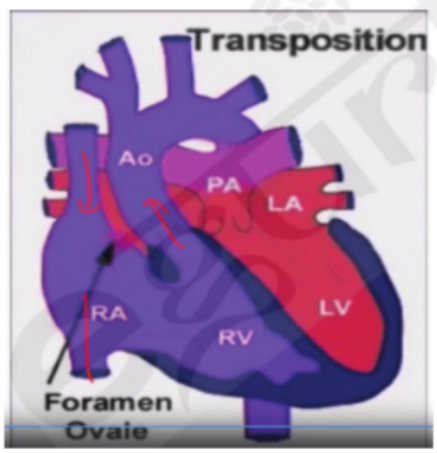

Telegram - @Latestpgnotes

Transposition of Great vessels (TGV)

- Non spiraling of conotruncal septum

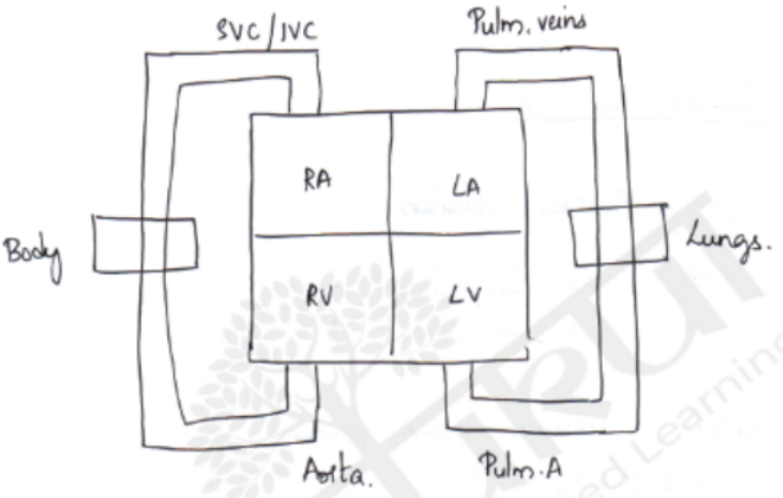

D-TGA.

- Cyanosis immediately after birth.
- Rx:
  - PGE1
  - Rashkind atrial septostomy (immediately) } → later surgery.
- Xray - 'Egg on string' appearance
  'Egg on side' appearance.

Telegram - @Latestpgnotes

Following pdfs notes are available free →
1 → marrow edition 4 notes(latest optha notes also available) , marrow qbank , marrow pearls
2-> prepladder notes, prep rapid revision 2.0,prepladder treasures 3-> Notespaedia devesh mishra pathology notes, notespaedia marrow Ecg, Notespaedia elite optha
For more
4-> egurukul - - >aswini Kumar anatomy notes, dermatology notes, medicine by thameem sir, ortho notes, physio notes, radio notes(all by notespaedia)
5->all standards books and review books Telegram - @latestpgnotes
6->Notes on demand and many more premium notes are will available free very soon Telegram : @latestpgnotes For more latest notes, join the telegram channel @latestpgnotes
For neet pg discussions join telegram group @neetpgdiscussion
For more latest notes, join the telegram channel @latestpgnotes
Click on link below to join our telegram channel

For more latest notes, join the telegram channel @latestpgnotes For neet pg discussions join telegram group @neetpgdiscussion For group discount upto 40-50% on any lecture app or individual app dm @drnash1

L- TGA (Corrected TGA)

- No cyanosis

Surgeries for TGA:

- Senning & Mustard operation:
  - RA blood directed to LV
  - LA blood directed to RV.
- Jantene arterial switch procedure.
  - Best treatment

Rashkind's septostomy

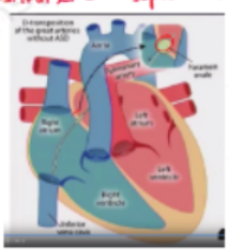

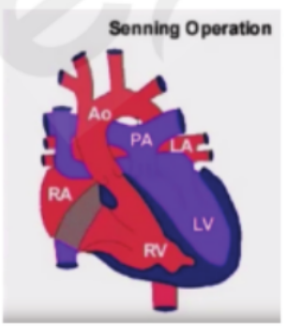

Jantene arterial switch

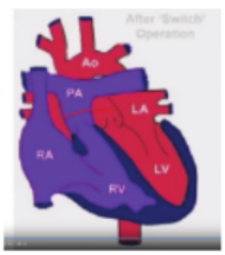

Telegram - @Latestpgnotes

Truncus arteriosus

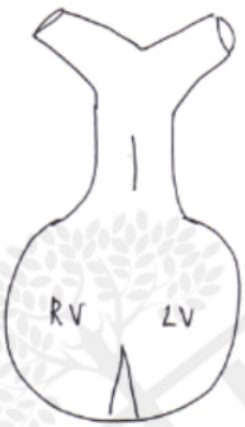

Common trunk opening for RV & LV.

- 33% associated with (R) sided aortic arch
- Not a ductus dependant condition*
- Single S_2
- ECG – Biventricular hypertrophy.

Rx: Truncus repair
- L VSD patched
- L Valved conduit.

Telegram - @Latestpgnotes

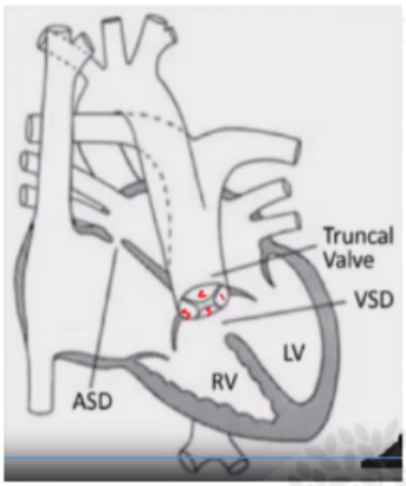

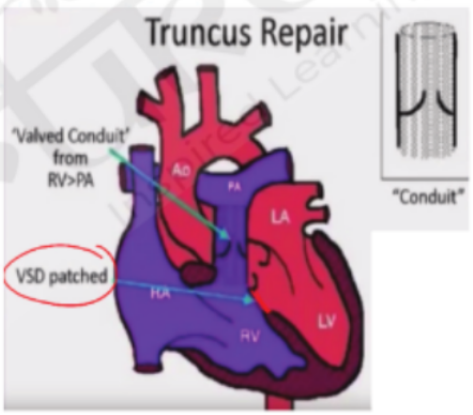

Telegram - @Latestpgnotes

Ventricular septal defect

→ Anatomically,

Inlet
Trabecular
Outlet → associated ↑ AR*.
Membranous → (M.C) in adult
Muscular → (M.C) in birth → spontaneous closure.

→ Echo classification:

Small VSD – <33% of aortic annular size – Asymptomatic
Moderate VSD – 33% – 75% " " "
Large VSD – >75% " " "
↳ early symptoms

→ Restrictive VSD – Qp:Qs – < 1.4 : 1
Moderate restrictive – " " – 1.4 – 2.2 : 1
Non restrictive – " " – >2.2 : 1

Telegram - @Latestpgnotes

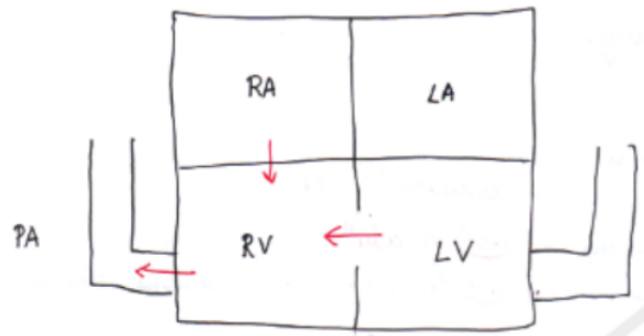

$Q_P > Q_S$

Symptoms

Restrictive

Asymptomatic

Non-restrictive

CCF

- Failure to thrive
- Sweating
- Fatigue during feeding

Pulm HTN

R → L

- Cyanosis
- CCF.

Telegram - @Latestpgnotes

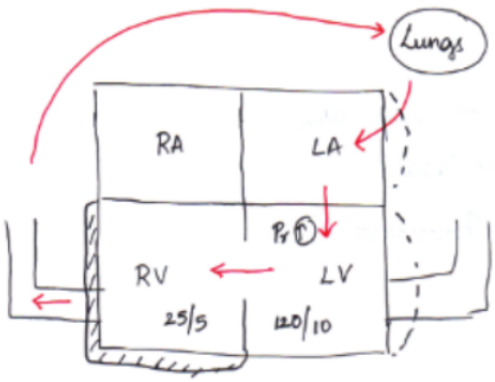

LV- dilates
RV- hypertrophies

- Apical impulse shifted outward
- Pansystolic murmur → best heard in left lower parasternal area.

Smaller VSD → ↑ turbulance → louder murmur
Large VSD/ Non-restrictive → No turbulance → soft murmur

- Ejection systolic murmur in pulmonary area
- Diastolic murmur in mitral area.
- S_3 (+) - Left sided
- Pulm HTN → RVH

Telegram - @Latestpgnotes

Pulm HTN

- Loud P_2 → Pulm area
- S_2 split → Narrow.
- RVH → Parasternal heave

Eisenmenger's

R ⟶ L shunt

- Absent Pan systolic murmur [as gradient is less]
- Polycythemia
- Cyanosis
- Loud P_2.
- Do not close the shunt.

Indications for closure of VSD :

$Q_p : Q_s$ → > 1.5 : 1 + Symptoms.

$Q_p : Q_s$ → > 2 : 1 [even if Asymptomatic]

Telegram - @Latestpgnotes

Atrial septal defect

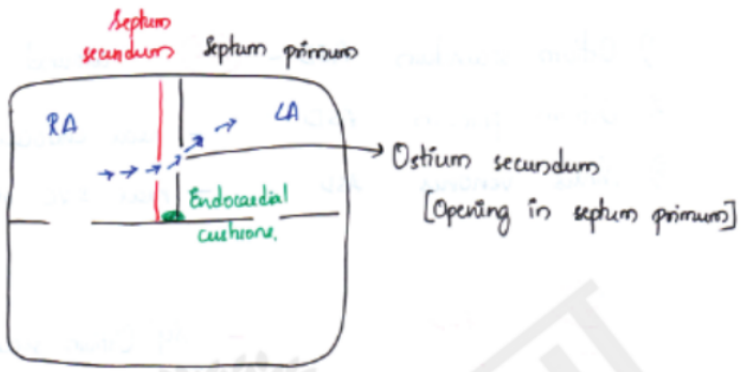

After birth :

- Due to umbilical V clamping, less blood reaches RA
  ↓
  RA pressure ↓

- Lungs expand → Pulmonary resistance ↓ → Blood from pulm. V into RLA → LA pressure ↑

Patent foramen ovale → 20-25% normally.

Telegram - @Latestpgnotes

Types :

1) Ostium secundum ASD - (M.C) - around foramen ovale
2) Ostium primum ASD - near endocardial cushions
3) Sinus venosus ASD - near SVC or IVC

(M.C) ASD - Ostium secundum

(M.C) in Down's syndrome - Ostium primum

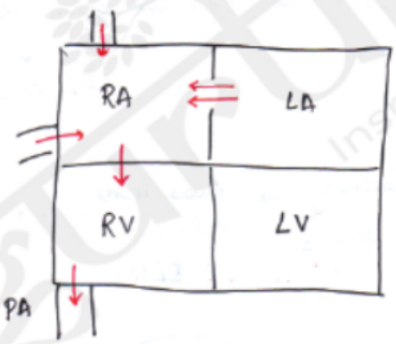

- Ejection systolic murmur in Pulmonary area.
- Mid diastolic murmur in Tricuspid area.
- $A_2 - P_2$ → wide & fixed
- Right sided S_3.
- Atrial arrythmias

Telegram - @Latestpgnotes

Why wide fixed A_2-P_2 split ?

During inspiration : Due to suction → more blood comes from SVC & IVC

& Lungs expand → more blood retained in lung → less blood comes to LA → less shunt

∴ A_2-P_2 remains fixed.

During expiration : Less blood from SVC & IVC ; More blood from shunt.

- ECG → - RBBB , Right axis deviation
  - RVH. when pulmonary HTN develop.
- Eisenmengerisation [shunt reversal]
  - ↳ A_2-P_2 - narrow.

Telegram - @Latestpgnotes

Ostium primum defect

associated with mitral valve defect
[cleft mitral valve]

★ ECG → Left axis deviation

CFs:

- Exercise limitation
- Dyspnea
- Pulm HTN → heart failure
  Cyanosis.

Investigations:

- ECG - Right axis deviation
  RBBB
  except - O. primum → Left axis deviation
- Echo - Bubble study

Telegram - @Latestpgnotes

℞:

- $Q_p : Q_s$ ≥ 1.5 : 1 + Symptomatic
  ⇓
  Closure.

- $Q_p : Q_s$ ≥ 2 : 1
  ⇓
  Closure.

- $Q_p : Q_s$ < 1.5 : 1
  ⇓
  Follow up.

- $Q_p : Q_s$ ≥ 1.5 : 1 + Asymptomatic

- Once pulm HTN develops → No closure.

Ostium secundum → Device closure

O. primum & sinus venosus → Surgical closure.

Telegram - @Latestpgnotes

COARCTATION OF AORTA

- **PREDUCTAL** — Pediatric (Infantile)
- **POSTDUCTAL** — Adults

PREDUCTAL

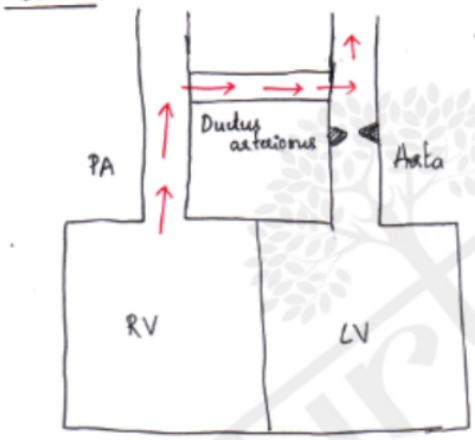

→ Cyanosis in lower limbs compared to upper limbs.

POSTDUCTAL [Adults]

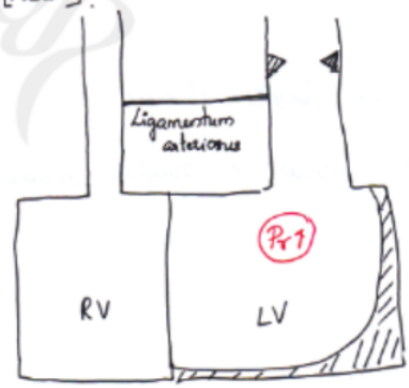

- Turner's syndrome
- Ass ↑ Bicuspid aortic valve
- Berry aneurysms
- VSD
- Mitral valve defects

Telegram - @Latestpgnotes

CFs:

- HTN (mc presentation) → Lower limbs pulses feeble than upper limbs.

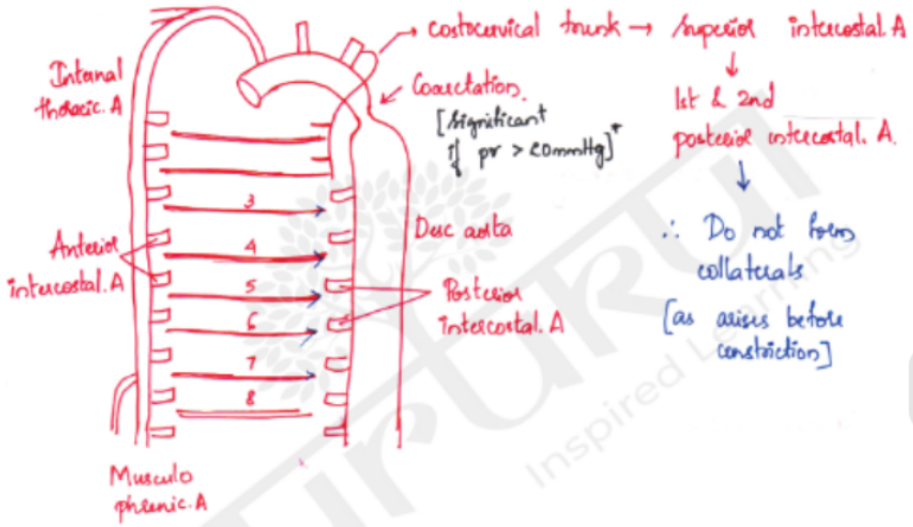

- Rib notching occurs most commonly from 4 – 8th ribs.
  [Inferior rib notching]
- Xray → 'figure of 3' sign

Rx:

- Balloon angioplasty
- Surgical Repair.

Telegram - @Latestpgnotes

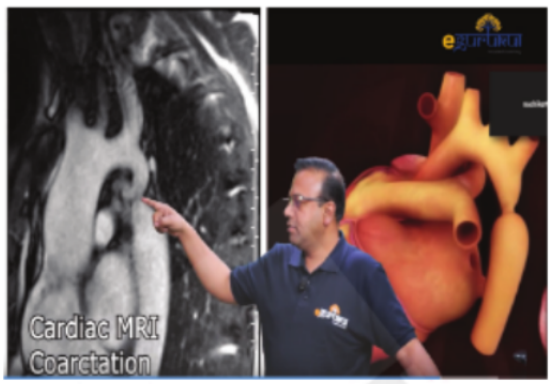

Inferior rib notching.

Telegram - @Latestpgnotes

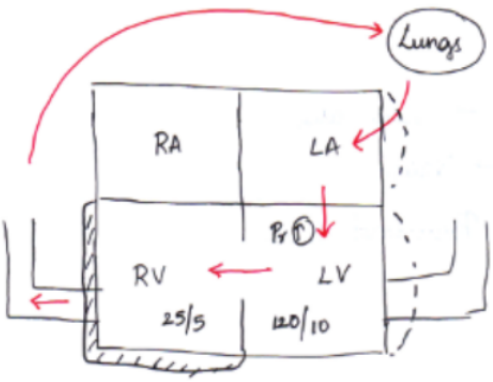

LV- dilates
RV- hypertrophies

- Apical impulse shifted outward
- Pansystolic murmur → best heard in left lower parasternal area.

Smaller VSD → ↑ turbulance → louder murmur
Large VSD/ Non-restrictive → No turbulance → soft murmur

- Ejection systolic murmur in pulmonary area
- Diastolic murmur in mitral area.
- S_3 (+) - Left sided
- Pulm HTN → RVH

Telegram - @Latestpgnotes

Pulm HTN

- Loud P_2 → Pulm area
- S_2 split → Nassons.
- RVH → Parasternal heave

Eisenmenger's

R ⟶ L shunt

- Absent Pansystolic murmur [as gradient is less]
- Polycythemia
- Cyanosis
- Loud P_2.
- Do not close the shunt.

Indications for closure of VSD :

$Q_p : Q_s$ → > 1.5 : 1 + Symptoms

$Q_p : Q_s$ → > 2 : 1 [even if Asymptomatic]

Telegram - @Latestpgnotes

Atrial septal defect

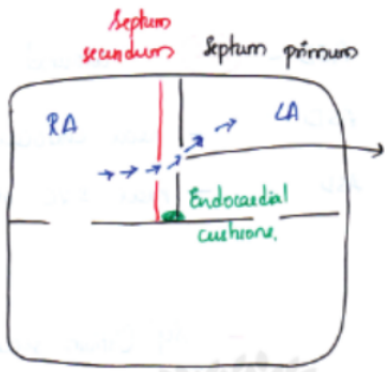

Ostium secundum
[Opening in septum primum]

After birth :

- Due to umbilical V clamping, less blood reaches RA
  ↓
  RA pressure ↓

- Lungs expand → Pulmonary resistance ↓ → Blood from pulm. V into RLA → LA pressure ↑

Patent foramen ovale → 20-25% normally.

Telegram - @Latestpgnotes

ISHEMIC HEART DISEASE

Coronary blood flow :

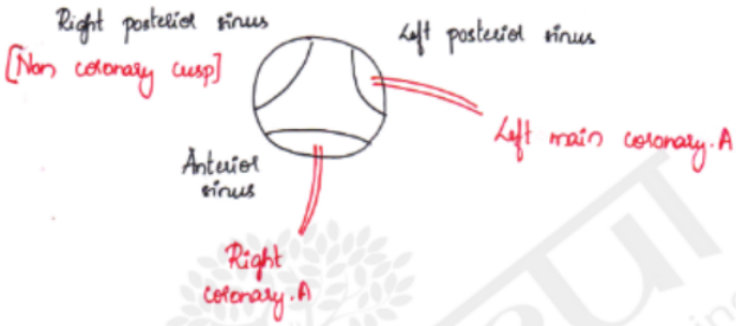

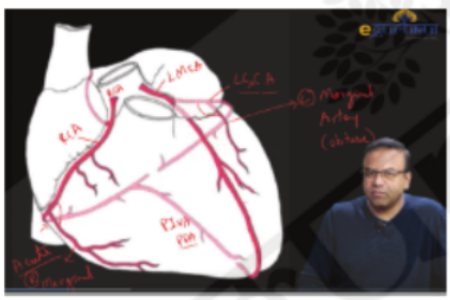

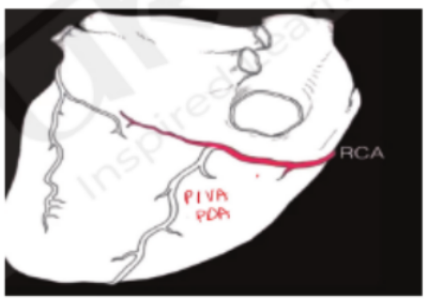

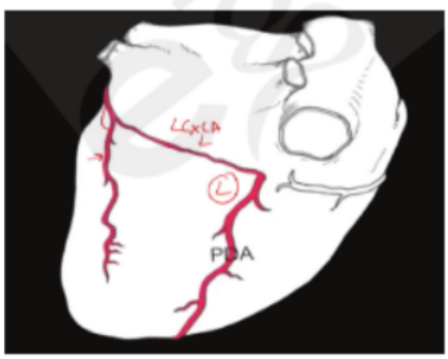

Image : 8:38

Co-dominance.

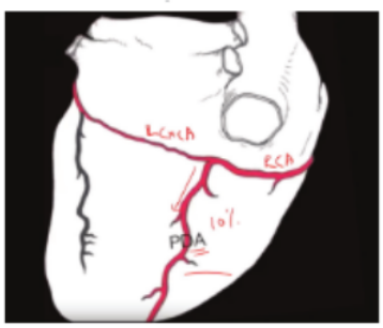

Telegram - @Latestpgnotes

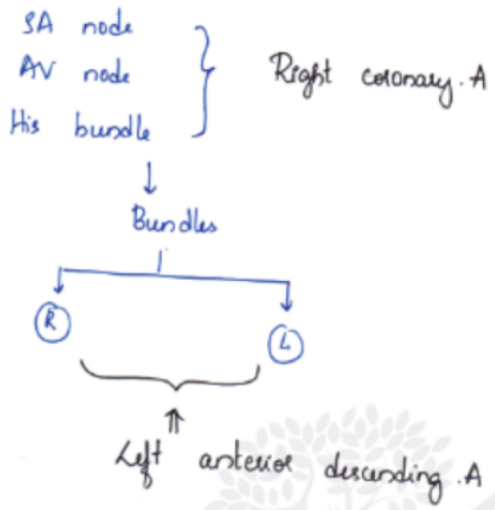

Areas supplied :

RCA :

- Most of RV
- Diaphragmatic surface of LV
- Postero - Inferior $\frac{1}{3}^{rd}$ of IVS
- RA & part of LA
- SAN & AVN
- LBBB [small branches]

LCA

- Most of LV
- Small area of RV adjacent to IV groove
- Anterior $\frac{2}{3}^{rd}$ of IVS
- Most of LA
- RBB & LBB

Telegram - @Latestpgnotes

ECG localisation of MI

Infarct location	Leads	Likely artery involved
Inferior wall MI *	II, III, aVF	RCA / Left circumflex.
Septal MI	$V_1 - V_2$	LAD
Anterior wall MI *	$V_3 - V_5$	LAD
Anteroseptal	$V_1 - V_4$	LAD
Extensive anterior MI	I, aVL, $V_1 - V_6$	LAD
Lateral wall MI *	I, aVL, $V_5 - V_6$	Circumflex
High lateral wall MI	I, aVL	Circumflex
Posterior wall MI	Prominent R in V_1	RCA or Circumflex
Right ventricular MI	ST elevation in V_1 & right sided V_4 with anterior wall MI	RCA

Telegram - @Latestpgnotes

IHD - 2

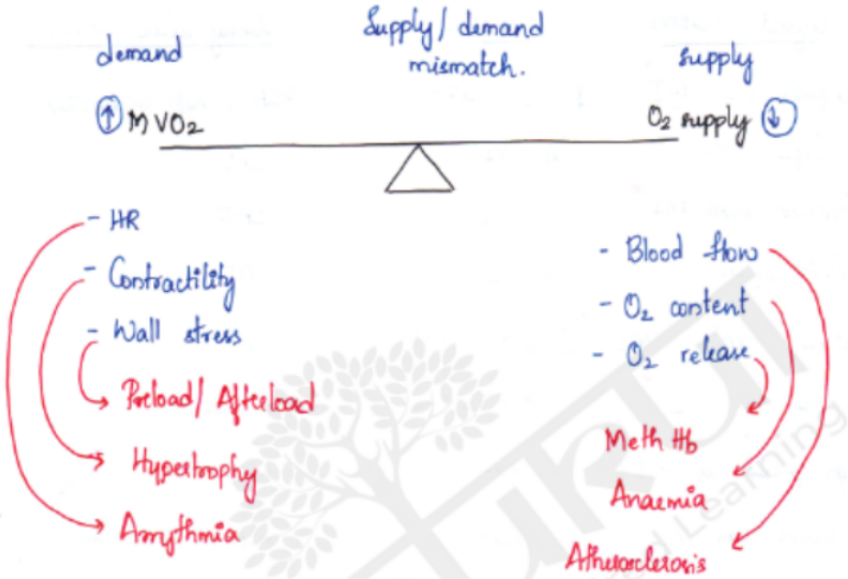

Risk factors :

Modifiable	Non modifiable
- Smoking - most easily preventable risk factor	- Age
- Dyslipidemia	- Sex
- Chronic stress	- Family history of premature CAD
- Sleep disorders	- Post menopausal
- HTN	
- Diabetes - most worst risk factor	
- Obesity	
- Sedentary lifestyle	

Telegram - @Latestpgnotes

ASCVD Risk score

Patient

Age
Sex
Race

- Total cholesterol
- HDL

- SBP
- HTN - Rx
- Smoking.
- Diabetes

Lipids :

$$LDL = \text{Total cholesterol} - \left(HDL + \frac{TG}{5}\right)$$

Guidelines for statins :

Pt with cardiovascular disease ⟶ Statins

↓ No

LDL > 190 mg/dL ⟶ Statins

↓ No

If diabetic & LDL - 70-189 mg/dL ⟶ Statins

↓ No

ASCVD score > 7.5% in >40 yrs pt ⟶ Statins.

Telegram - @Latestpgnotes

Statins used:

High intensity statins:

		For Indians
20 - 40 mg	Rosuvastatin	- 20mg.
40 - 80 mg	Atorvastatin	- 40mg

In patients at very high risk whose LDL-C levels remain ≥70mg/dL on maximally tolerated statin & ezetimibe therapy, adding PCSK-9 inhibitor is reasonable.

- LDL - levels should be ↓ to < 70mg/dL.
- PCSK-9 inhibitors - reduce LDL maximally.
  - Evolocumab
  - Alirocumab

Telegram - @Latestpgnotes

CVD-3

ANGINA

Typical angina :- All (3)

1. Characteristic substernal chest pain
2. Provoked by exertion/ stress
3. Subsides with rest / nitrates

Chest pain : Compressive retrosternal pain radiating to arm, upto jaw or umbilicus.

Levine's sign - fist over chest.

Atypical angina : (2) out 3.

Non anginal pain : None / (1) out of 3.

In pericarditis : pain (↓) on bending forwards.

Pt with chest pain :

Investigations :
- Clinical
- ECG
- Cardiac markers
- Others - Echo.

Telegram - @Latestpgnotes

Stress test :

Stress	Test
• Excercise treadmill	• ECG
• Vasodilators - Adenosine	• Echo
- Regadenoson	• Myocardial perfusion imaging
• Inotropes - Dobutamine*	• PET, CT- angio.

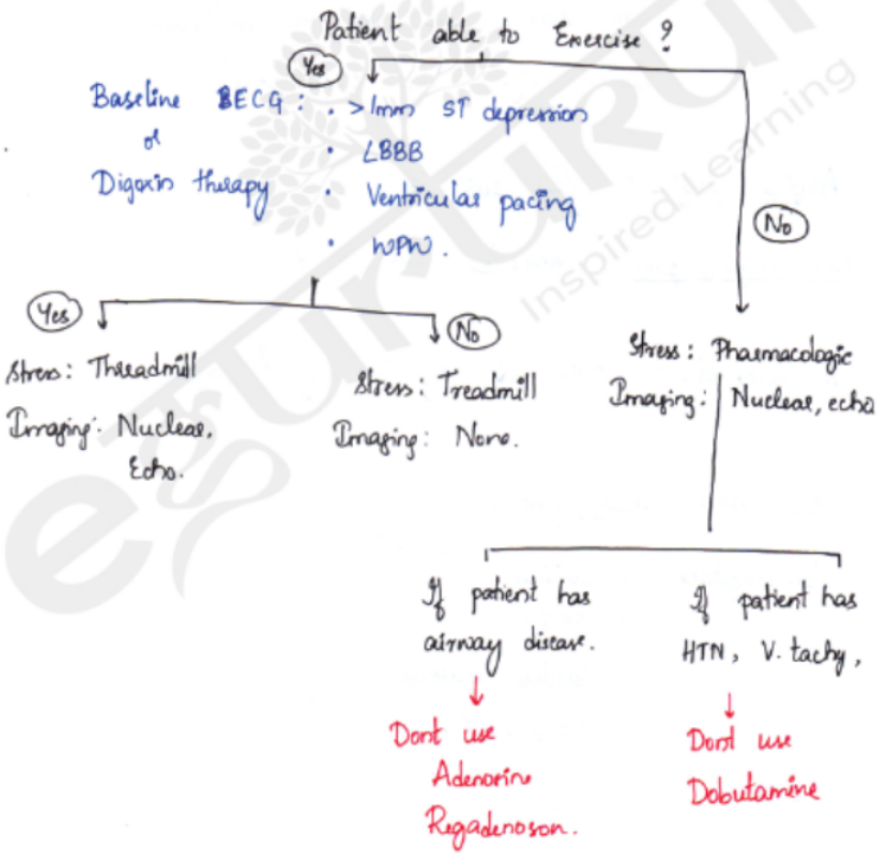

Telegram - @Latestpgnotes

Positive stress test

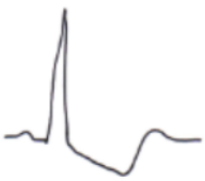

Negative stress test

- Nuclear imaging :

  $Thallium^{201}$, Tc^{99}

  Heterogeneity of flow shows ischemia.

  - Physiologic, not anatomic
  - High sensitivity, lower specificity.

- CT :

  NCCT : CT calcium score.

Dystropic calcification can be picked up.

Telegram - @Latestpgnotes

- GRACE SCORE → To decide ischemic heart disease or not.

Myocardial viability testing:

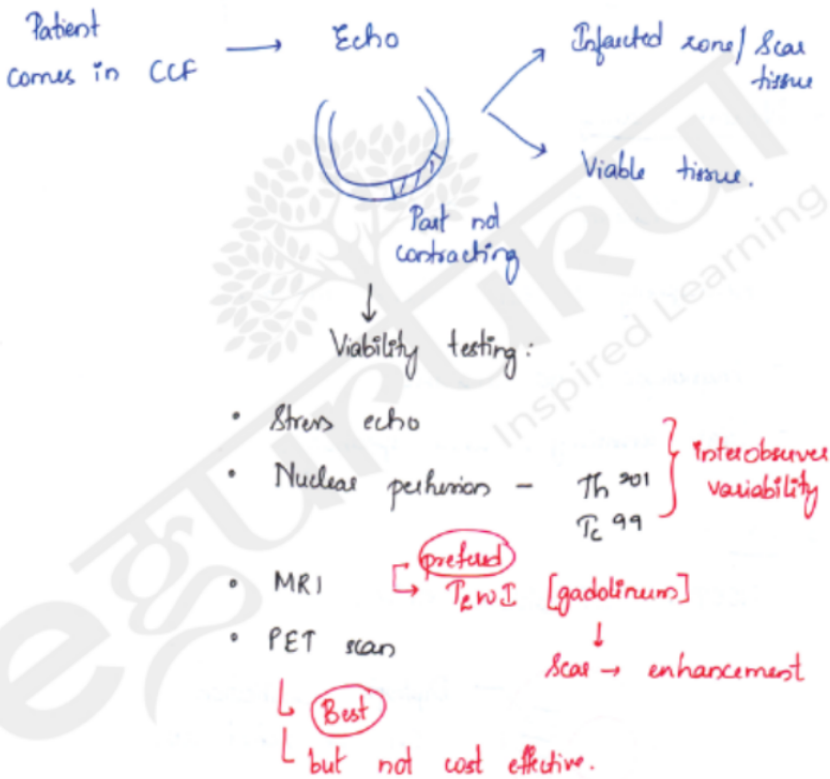

Telegram - @Latestpgnotes

Th^{201} → acts like K^+

If $Na^+ - K^+$ pumps are active
then Na^+ is pumped out
& K^+ is pumped in.
↓
∴ Th^{201} acts like K^+
& should be present inside the
cell in normal myocardium

delayed scan.

Delayed uptake of Thallium → Tissue is alive → Stunned / Hibernating

No uptake at all → Non-viable scar tissue.
[Always cold]

Telegram - @Latestpgnotes

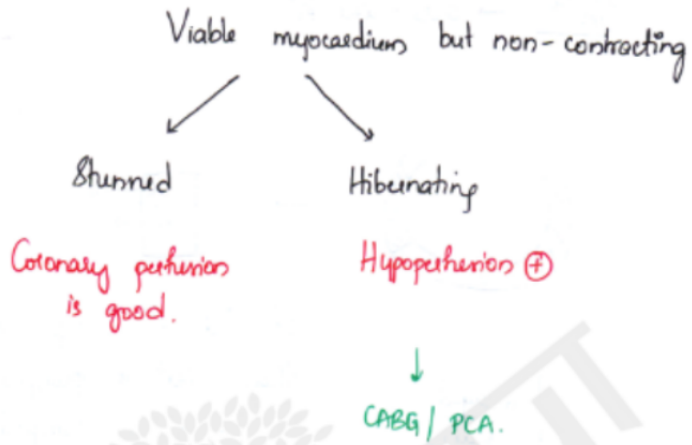

Telegram - @Latestpgnotes

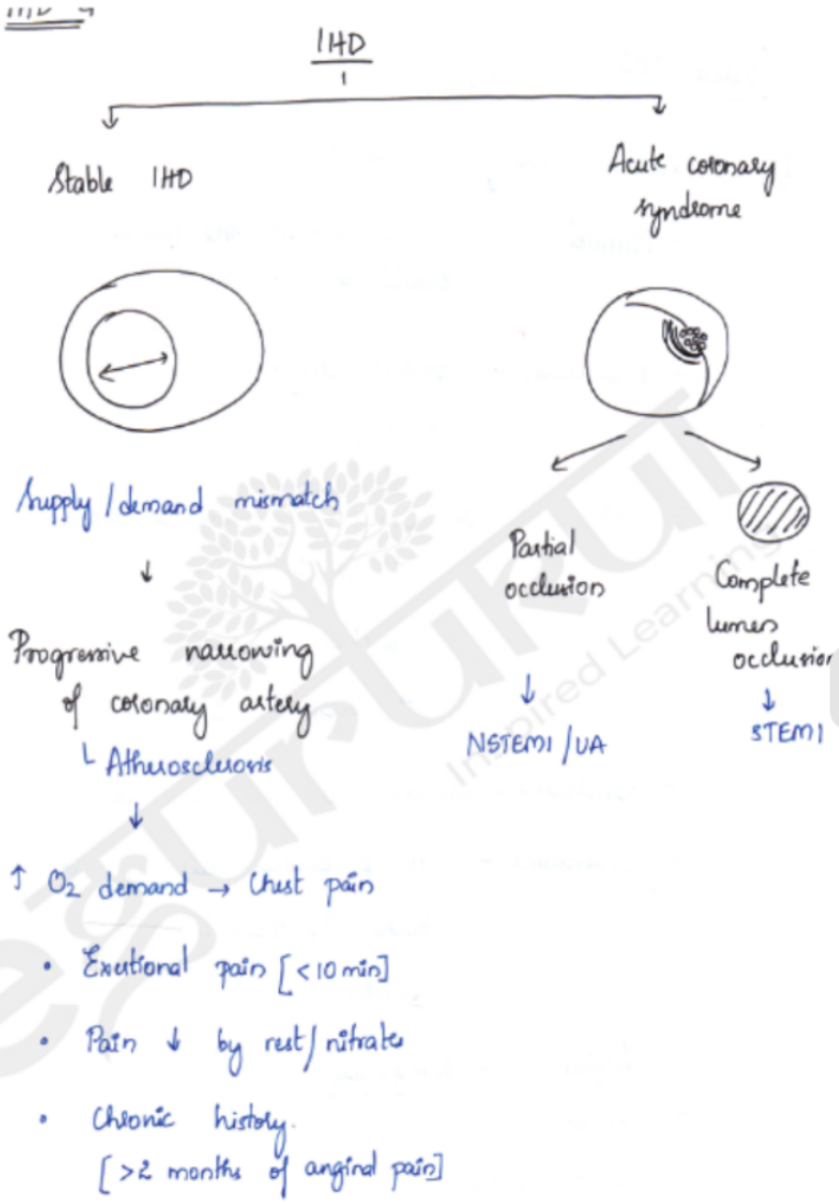

Telegram - @Latestpgnotes

Stable IHD

℞: Medical therapy (preferred)

- Nitrates – 8-12 hr nitrate free interval should be maintained
- β blockers – prevent arrythmia
  HR - 60/min
- CCBs – If added along with β blockers
  ↳ Dihydropyridine
  If β blockers contraindicated
  ↳ Verapamil / Diltiazem
- Ranolazine - acts on late Na^+ channels
- Ivabradine – If β blockers contraindicated
  blocks I_f channels
  ↓ HR.
- Aspirin – 81 mg / day
- Statins
- BP – control
  ↳ start ℞ if BP is > 130/80.
- Blood sugar control.

Telegram - @Latestpgnotes

If patient has angina despite medical therapy

↓

Go for angiogram

Acute coronary syndrome

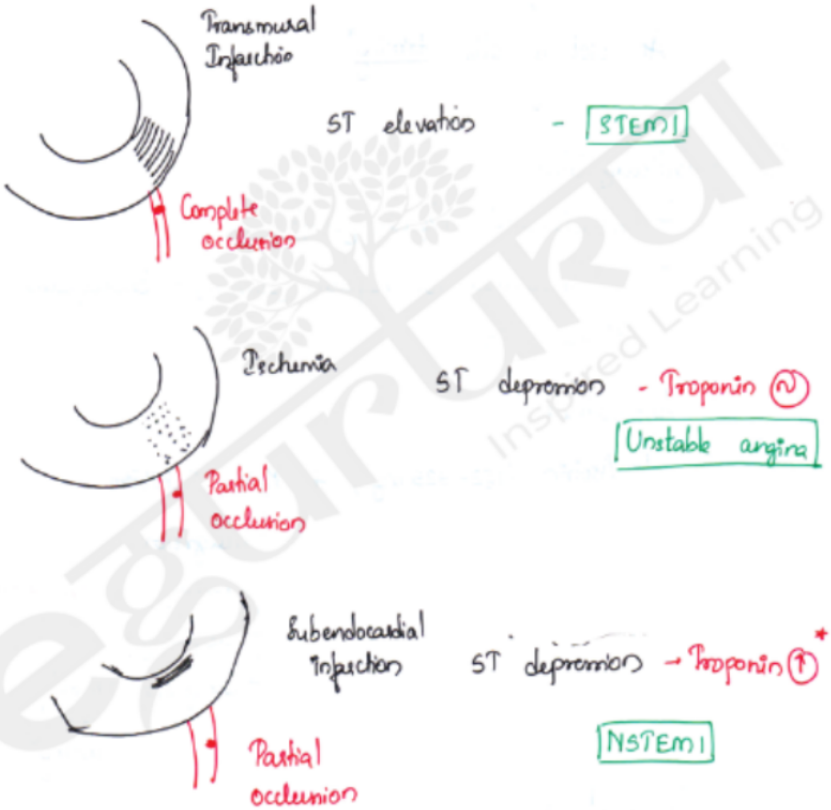

Telegram - @Latestpgnotes

UA/ NSTEMI

- Chest pain - at rest
- > 10min
- Crescendo pain

↓

As clot is still forming*

↓

℞: • Anticoagulation:
  - Unfractionated Heparin [UFH]
  - Low molecular wt heparin [LMWH] - Enoxaparin
  - Bivalirudin

• Antiplatelets:
  - Aspirin (162-325 mg) + P_2Y_{12} inhibitors
    - Ticagrelor
    - Prasugrel → c/I stroke*
    - Clopidogrel
    - Cangrelor - most rapidly acting.

Prasugrel advice:
- There should be no H/O TIA or stroke
- Pt definitely going for procedure.

Telegram - @Latestpgnotes

- $IIb/IIIa$ inhibitors
- Nitrates
- β blockers
- O_2 → only if $SaO_2 < 90\%$.

GRACE score > 140
TIMI score ≥ 3
} → Go for procedure.

TIMI score :

- Age ≥65 yrs
- ≥3 traditional CAD risk factors
- Documented CAD with ≥50% diameter stenosis
- ST segment deviation
- ≥2 anginal episodes in the past 24 hrs
- Aspirin use in past week
- Elevated cardiac biomarkers (CK / troponin)

Telegram - @Latestpgnotes

STEMI

- Chest pain > 30 min

Myocardial injury : ↑ Tn in pt of chest pain

Myocardial infarction : ↑ Tn plus atleast 1 of following :

- Symptoms of myo ischemia
- ECG changes → ST elevation > 1mm in ≥2 leads
  Limb leads >1mm
  Anterior chest leads - >2mm [V_2-V_3] [Age >40yrs]
  - >2.5mm [Age <40yrs]
- Pathological Q waves → marker of cell death. [6-8 hrs after chest pain]
- Imaging evidence - Regional wall motion abnormality (RWMA)
- Coronary thrombus by angio / autopsy.
- New onset LBBB.

Telegram - @Latestpgnotes

MI:

Type 1: Coronary artery disease - plaque rupture.

2: Demand supply mismatch - Arrythmia
Coronary A spasm

3: MI associated death before T_n sampling

4: MI in patients with PCI in past.
[T_n x 5 times (N)]

5: MI in patients with CABG in past.
[T_n x 10 times (N)]

Markers:

1-2 hours - Myoglobin | 1-3 hours - Highly sensitive troponin.
2-4 hours - CK
4-8 hours - Troponin
6-12 hours - CK-MB

Telegram - @Latestpgnotes

Management : STEMI

- Aspirin - 325mg
- Rest
- ECG
- O_2 only if $SaO_2 < 90\%$
- Nitrates
- β blockers - oral
  - C/I in CCF, EF<40%, heart blocks
- Morphine - i.v
- P_2Y_{12} Inhibitor - Ticagrelor / Prasugrel / Clopidogrel
- Anticoagulation - UFH / LMWH / Bivalirudin

Thrombolytic therapy

Primary percutaneous coronary intervention [PCI]

Broken pieces of clot

- Broken pieces are removed
- Expand constricted zone using balloon.
- Stent maintain patency.

Telegram - @Latestpgnotes

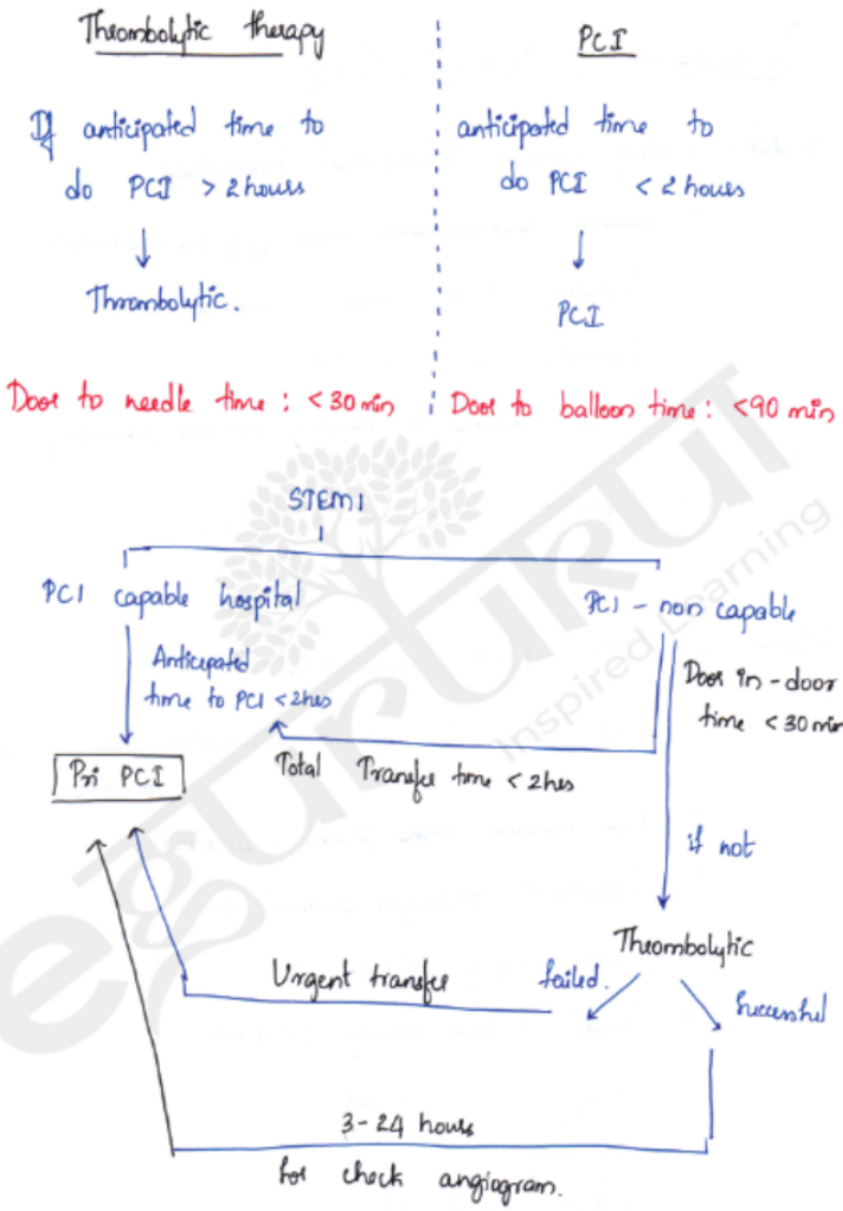

Telegram - @Latestpgnotes

Contraindications to thrombolytic therapy

Absolute:
- Any previous intracerebral hemorrhage
- Known cerebrovascular lesion (e.g AV malformation)
- Ischemic stroke within 3 months
- Suspected aortic dissection
- Active bleeding or bleeding diathesis (excluding menses)
- Significant closed head or facial trauma within 3 months

Relative:
- H/O chronic, severe HTN
- Severe uncontrolled HTN on presentation (SBP >180 mmHg or DBP >110 mmHg)
- H/O ischemic stroke (>3 mo), dementia
- Traumatic / prolonged (>10 min) CPR
- Major surgery (<3 wks)
- Recent internal bleeding (2-4 wks)
- Allergy to streptokinase
- Pregnancy
- Active peptic ulcer disease

Telegram - @Latestpgnotes

★ Thrombolytic used only (<12 hrs) of onset of chest pain

except if patient has

- symptoms of ongoing ischemia
- ECG - new onset ischemic features

↓

(12-24 hrs) - thrombolytic can be given.

>24 hrs → absolute c/I

★ Pri PCI - best done (<12 hrs)

Heart failure
↓EF
Unstable
} can be done even if (>12 hrs).

After PCI / thrombolytic → Dual anti-platelet therapy

Aspirin + P_2Y_{12} inhibitor

Minimum for (1 yr)

except in procedure for stable IHD → (6 months)

Telegram - @Latestpgnotes

Acute coronary syndrome

Telegram - @Latestpgnotes

CABG: Coronary artery bypass graft

- Triple vessel disease (Diabetic)
- Proximal LAD lesion
- Left main coronary artery (LMCA) >50% stenosed

↓

Best graft - Internal mammary artery (Left > Right)

Least " - Saphenous vein
[High reocclusion rate]

Telegram - @Latestpgnotes

Medications during discharge:

- DAPT - Aspirin + P_2Y_{12} inhibitor
- ACEI
- Statins
- HF / Diabetic - Aldosterone receptor blockers
  Eplerenone / Spironolactone
- β blockers

Complications:

- Free wall rupture - 4 - 7th day.
  - Tamponade
  - Syncope / Collapse
  - Mortality
- Papillary muscle rupture
- VSD.
- Cardiogenic shock [LV dysfunction]
- Arrythmias

Telegram - @Latestpgnotes

- Patient with hypotension
  ↓
  Pansystolic murmur.
  ↙ ↘
  Septal perforation (Acute VSD) → Parasternal
  Papillary muscle rupture (Acute MR) → Axilla / back.

- Intraaortic balloon pump
  - used to maintain BP until taken for surgery.
  - supportive
  - done after PCI

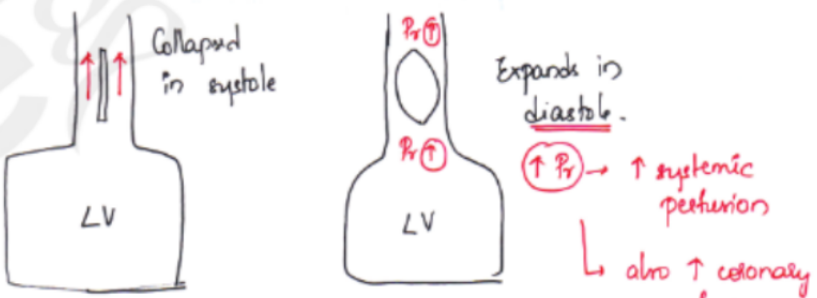

Telegram - @Latestpgnotes

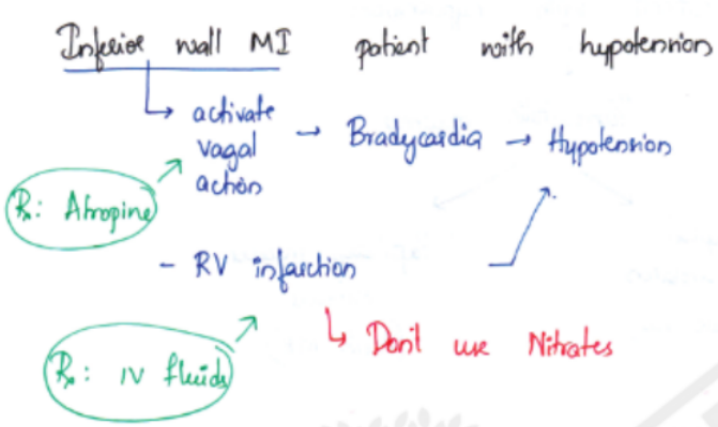

Post MI arrythmia:

ICD - Intracardiac cardioverter / Defibrillator.

- put after >40days of MI
- EF < 35% [NYHA class 2/3]
- Post PCI/CABG - After 3 months.

Telegram - @Latestpgnotes

VALVULAR HEART DISEASE

Categories:

Non severe — A, B — Asymptomatic

C — Asymptomatic

Severe — D — Symptomatic

A – At risk

B – Mild disease but progressive

C – Severe asymptomatic
- C_1 – compensated ventricles
- C_2 – decompensated ventricles
  - EF – ↓.

Surgical intervention

Telegram - @Latestpgnotes

VHD - Part 1 - Aortic stenosis

- Congenital → Bicuspid aortic valve - calcified
- Rheumatic - (M.C) cause of AS in developing countries
- Calcification (Degenerative) of aortic valve.
  ↳ (M.C) cause in developed countries.

Bicuspid aortic valve:

- 2% of normal population
- Ejection click (+) ★
- Associations:
  - Turner's syn
  - Coarctation of Aorta
  - Dissection of Aorta

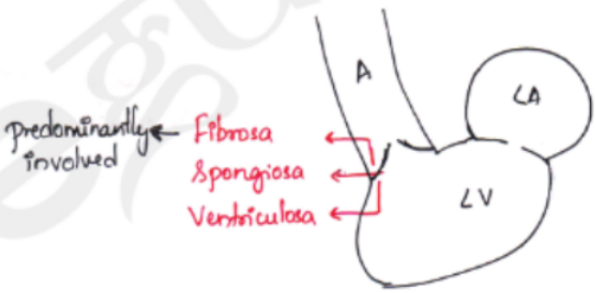

★ Inflamation → Valvular damage → Calcification.

Telegram - @Latestpgnotes



Telegram - @Latestpgnotes

CFs :

- Exertional angina → Survival 5 yrs
- Syncope - exertional [↓ blood flow to brain] → 3yrs
- Exertional dyspnea. → Heart failure. → 2 yrs.

Examination :

- Pulse : Pulsus parvus et tardus & carotid shudder.
  - slow raising, low volume pulse
- BP : low pulse pressure
  - Systolic BP ↓ - as LV doesn't pump good amount of blood.
- Sustained apical impulse
- Auscultation : Right 2nd ICS - sternal
  - ↓
  - Ejection systolic murmur.

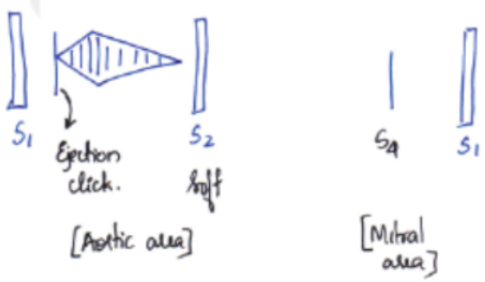

Telegram - @Latestpgnotes

Gallavardin's effect/:: AS murmur getting conducted phenomenon to mitral area.

Severe AS :

- More (later) the ejection click & murmur, more severe it is.
- Duration of murmur (↓) → Severity (↑).

- Dobutamine stress test
  ↳ to differentiate → true AS and weak LV.
- Nitroprusside test → for low flow, low gradient aortic stenosis.

- If no ejection click → pathology is in supravalvular/ subvalvular area.

- Murmur vary with respiration → Right heart problem
  Murmur did not vary with resp → Left heart problem

Telegram - @Latestpgnotes

Normal :

A_2 P_2.

Inspiration A_2 P_2 → Split becomes wide.

AS : P_2 A_2

Inspiration P_2 A_2 - Split becomes narrow

In expiration - split is heard

Inspiration - single sound.

Reverse split.

If in inspiration - A_2-P_2 split heard

⇓

Rule out Aortic stenosis.

Aortic area:

	Ejection click	Ejection systolic murmur
• Valvular AS	✓	✓
• Flow murmur (of) Supra/ subvalvular AS	×	✓
• Bicuspid aortic valve	✓	×

Telegram - @Latestpgnotes

Williams's syndrome:

- Supravalvular AS
- Hypercalcemia*
- Elfin facies - Head doesnot develop properly
- Mental retardation.

Chr - 7 defect → elastin loss

- Premature aging of skin
- No ejection click.
  Ejection systolic murmur ⊕ → better auscultated on right side in 1st ICS.

Telegram - @Latestpgnotes

Severe AS

Jet velocity → ≥ 4.0 m/s

Mean gradient → ≥ 40 mm Hg

Valve area → ≤ 1.0 cm^2 [0.6 cm^2/m^2]

$P = 4V^2$ ** → Pressure across valve.

P → Pressure

V → Velocity

Inv:

CXR – - Post-stenotic dilatation

- Straightening of left border → LA dilation.

ECG – LVH – Left axis deviation

Echo – Calcified damaged valve with narrowing

Thicker LV.

Dg AR + AS ⇒ Rheumatic in origin.

Telegram - @Latestpgnotes

Treatment :

Asymptomatic (Stage D) ⟶ Aortic valve replacement

Severe AS + Asymptomatic

- Abnormal exercise treadmill test
- Planned for other cardiac surgery
- Progressive narrowing $\Delta V_{max} > 0.3 m/s$ / year
- LVEF < 50% *

} Aortic valve replacement

Transcatheter Aortic valve replacement [TAVR / TAVI]

Indications: - High surgical risk
- Bleeding diathesis.
- Intermediate surgical risk

After TAVI → patient is put on antiplatelet, not on anticoagulant.

Telegram - @Latestpgnotes

Limitations of TAVR:

- Stroke / Cerebral emboli
- Paravalvular regurgitation
- Need for permanent pacemaker
- Leaflet thrombosis

Telegram - @Latestpgnotes

VHD - Aortic Regurgitation

Causes :

Acute

- Infective endocarditis (m.c)
- Dissection of aorta
- Trauma

Chronic

- Rheumatic (m.c) in developing countries
- Degenerative calcific AV
  - (m.c) in developed
- Congenital
  - Bicuspid AV.
- Syphilis
- Spondyloarthropathy.
  - Ankylosing spondylitis
  - Reiter's syndrome.
- Rheumatoid arthritis
- Aortic root disease
  - Aortitis
  - Marfan's
  - Ehlers Danlos
  - Cystic medial degeneration
  - HTN
  - Aortic aneurysm

Telegram - @Latestpgnotes

PATHOPHYSIOLOGY :

Acute AR :

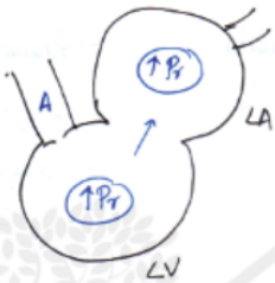

Sudden ↑ volume → ↑ End diastolic pressure → ↑ LA pressure → ↑ pressure in pulmonary circuit

↓

- Congestion
- Pulm edema

↓

Heart failure symptoms

* Fever & infective endocarditis + CCF symptoms
  stigmata

⊕

* - Wide pulse pressure
  - No classical AR murmur.

Telegram - @Latestpgnotes

℞:

- Nitroprusside
- Diuretics

↓

Urgent AV replacement.

Do not give :

- β blockers
- Intraaortic balloon

Chronic AR

Laplace's law : Wall stress $\propto \frac{P.r}{h}$

P- Pressure
r- radius
h- thickness.

In AR → ↑ radius to accomodate blood

[as ↑ radius → ↑ wall stress]

↓

to compensate → ↑ wall thickness

[↑ wall thickness → ↓ wall stress]

but wall cavity to thickness ratio is maintained.

Telegram - @Latestpgnotes

* LV hypertrophy : in AR
  - Eccentric
  - Sarcomere replication is in series.

Symptoms:

- Palpitations
- Discomfort → more in · supine · exertion
- Fatigue
- Exertional dyspnea
- Orthopnea
- PND
- Angina - As coronary blood flow mainly occurs in diastole, as in AR - valve is leaking & diastolic pressure ↓ Coronary BF ↓.
- Nocturnal angina.

Telegram - @Latestpgnotes

O/E :

- Pulse : Pulsus bisferiens



- Peripheral signs :

Corrigan's pulse/ Waterhammer pulse → Rapid rise & fall.

De musset's sign → Bobbing of head

Light house sign - Alternating redness & paleness of face

Muller's sign - Pulsations of uvula.

Quinke's sign - Pulsations occuring in nail bed.

- Femoral artery.

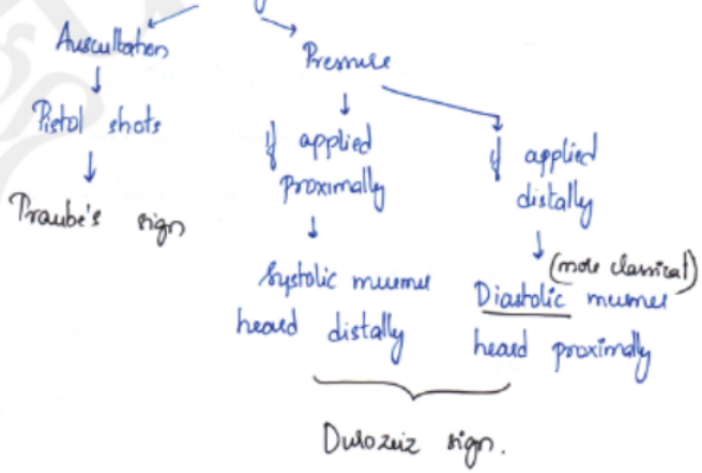

Telegram - @Latestpgnotes

- Hill sign: Systolic pressure difference between upper & lower limbs →

  (N) - <20 mmHg

  LL > UL - 20-40 mmHg - Mild
  40-60 mmHg - Moderate
  >60 mmHg - Severe.

- Becker's sign - Pulsations in retinal vessels.
- Mayne's sign - (↓) in diastolic pressure >15 mmHg on raising the arm.
- Rosenbach's sign - Pulsations of liver
- Gerhard's sign - Pulsation in spleen.

o BP →

SBP - (↑) - as both (N) blood & regurgitant blood squeezed out forcefully by Starling's law

DBP - (↓)

written as 150 / 60 - 0
↑ Muffled ↑ Absence of Korotkoff sounds

Telegram - @Latestpgnotes

- Pulse pressure – High
- Apical impulse – shifted down & out.
  – ill sustained.
- Thrill ±
- Auscultation:

- Harsh, high pitched, decrescendo murmur
- Heard best in Erb's area → Aortic valve ds [Left parasternal 3rd ICS]
- Patient sitting forward
- End of expiration.

If aortic root disease → best heard in aortic area [Right 3rd ICS]

Telegram - @Latestpgnotes

In mitral area:



Austin flint murmur – Mid diastolic murmur [MDM]
– rumbling murmur.
– S_3 (+)

Large jet of blood due to AR
↓
push the mitral valve & occlude it
↓
turbulence
↓
Mid diastolic murmur. [MDM]

Austin flint	MDM (mitral stenosis)
• S_1 – soft / (N)	• loud S_1
• S_3 (+) [low pitched, localised]	• Opening snap [High pitch, heard in large area]
• Hyperdynamic circulation [Peripheral signs] – ↑ pulse pressure	• (–)

Telegram - @Latestpgnotes

Aortic area

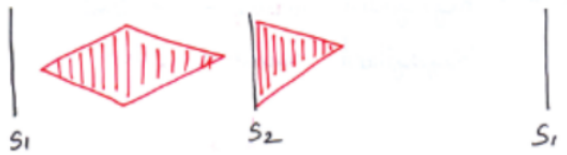

Flow murmur
[due to large volume]
Crescendo-decrescendo murmur.

- Echo - Regurgitant column
- CXR - Acute AR - Heart (N) in size
Pulm congestion (+)

Chronic AR - Large heart
Dilated aortic root

Cardiomegaly → Heart shadow >50% of chest.

- ECG - LVH, Left axis deviation
Left atrial enlargement ±

Telegram - @Latestpgnotes

Echo :

Severe AR – • Regurgitant volume – ≥ 60ml
• Regurgitant fraction – ≥ 50%

If • Ejection fraction (< 50%)*
• EF > 50% → End diastolic diameter → (> 65mm)*
End systolic diameter → (> 50 mm)*

Rx:

If symptomatic
or
Asymptomatic
- LVEF < 50%
- Other surgery
- LVEF > 50%
  but LVEDD > 65mm
  LVESD > 50mm

} Aortic valve replacement. (Surgical)

Drugs : ACEI, CCBs.

Telegram - @Latestpgnotes

VHD - MITRAL REGURGITATION

LV → Eccentric LVH.
LV dilatation.

$$EF = \frac{SV}{EDV}$$ ⇒ In regurgitant lesions ⇓ EF → ↑↑.

★ Low EF [<30%] → Contraindication for surgery.

Acute MR
↓
LA - not yet adapted to transmits pressure to pulmonary circulation
↓
Pulm HTN
↓
Right heart failure.

Chronic MR
↓
Adaptations ⊕
LA dilates
LV dilates & eccentric hypertrophy ⊕.

Telegram - @Latestpgnotes

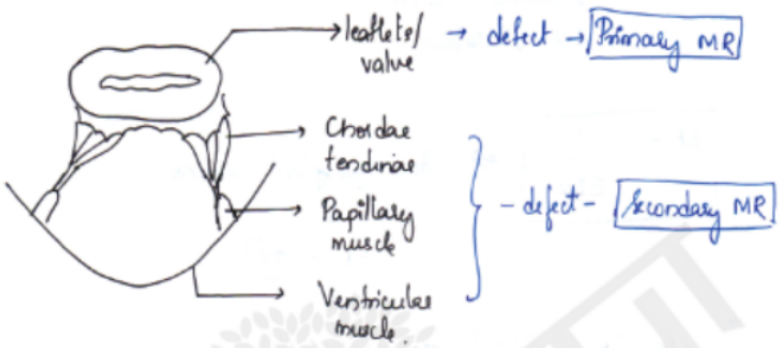

Causes:

Acute

- Infective endocarditis
- Acute rheumatic fever
- Chordae tendinae rupture [MVP]
  - Myxomatous degeneration
  - Trauma
  - Endocarditis
- Papillary muscle rupture - Post MI
  4-6th day.

Telegram - @Latestpgnotes

Symptoms in Acute MR:

- Cardiogenic shock
- Acute pulmonary edema
- CCF - Left heart - Dyspnea on exertion
  Orthopnea / PND
  Right heart - Pedal edema
  Ascitis, Hepatomegaly
  ↑ JVP

Auscultation:

S1 Early systolic murmur.

↓

As in acute MR,
LA is not dilated to accomodate more blood.
So, LA pressure ↑
rapidly reaching LV pressure. ∴ As there is no gradient - flow stops.
So murmur is not pansystolic.

Telegram - @Latestpgnotes

Management of Acute MR :

- Vasodilators are mainstay. (Nitroprusside)
- Inotropes - to support cardiac output & BP
- Intra-aortic balloon pump
- Diuretics → ↓ pulm edema.

↓

Stabilise the patient & then surgery.

Chronic MR

Causes:

Primary

- RHD
- MVP
- SLE (Libman sachs)
- Infective endocarditis.

↓

Valve surgery.

Secondary

- Coronary (ischemic) / Non ischemic cardiomyopathy
- Dilated cardiomyopathy
- HOCM

↓

Treat the cause.

Telegram - @Latestpgnotes

Carpentier's classification

Type I → (N) valve movement

Type II → ↑ mitral valve movement.
└ mitral valve prolapse.

Type III → Restricted mitral valve movement
└ Rheumatic / MI

Symptoms:
- Asymptomatic
- Palpitations
- Fatigue - as forward flow in aorta is (↓)
- Exercise limitation
- LA pr (↑) → pulm pr (↑)
- Dyspnea on exertion, orthopnea, PND.

* Syncope & angina → Aortic valve disease

Telegram - @Latestpgnotes

O/E :

Pulse : Ⓝ / Hyperdynamic

Irregularly irregular if Atrial fibrillation develops.

JVP - Ⓝ

Pulm HTN → Giant 'a' waves

A. fib → Absent 'a' waves

Apical Impulse - . Hyperdynamic

· Down & out displacement.

· Thrill ⊕ - Systolic.

Auscultation : Mitral area :

High pitched Pansystolic overshadows S_2 [S_2 not heard]

Mid diastolic murmur. [functional rumble]

If MS accompanied with MR →
- Thrill ⊕
- MDM - pathological [not functional]
- ↑ risk of Atrial fibrillation

Telegram - @Latestpgnotes

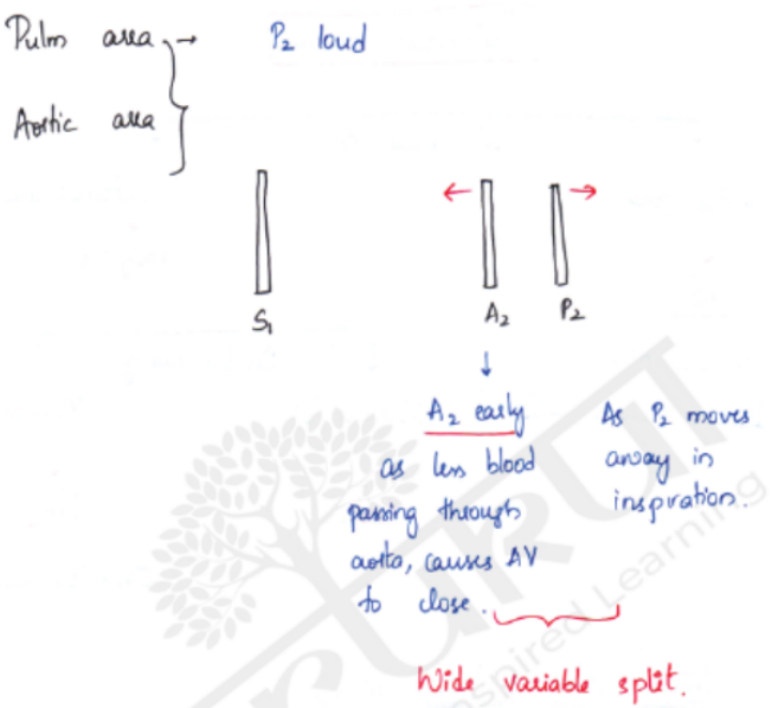

Telegram - @Latestpgnotes

Pansystolic murmur

best heard in

Mitral area → MR

↑ in expiration radiates towards axilla

Parasternal area → VSD / TR

On leg raising

Murmur ↓ → VSD

Murmur ↑ → TR

* JVP - 'cv' waves

Mitral valve prolapse (MVP)

Anterior MVP

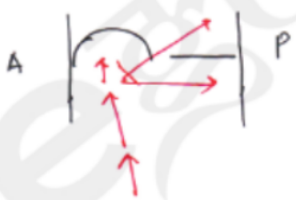

Blood hits anterior & direction is posterior

∴ conducts to axilla & infrascapular area

Posterior MVP

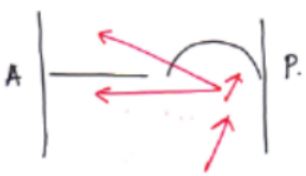

Blood hits posterior & direction is anterior

better auscultated in anterior chest / aortic area

Telegram - @Latestpgnotes

Pathophysio :

- Myxomatous degeneration
- Fibroelastic
- Barlow's - young pt
  very severe.

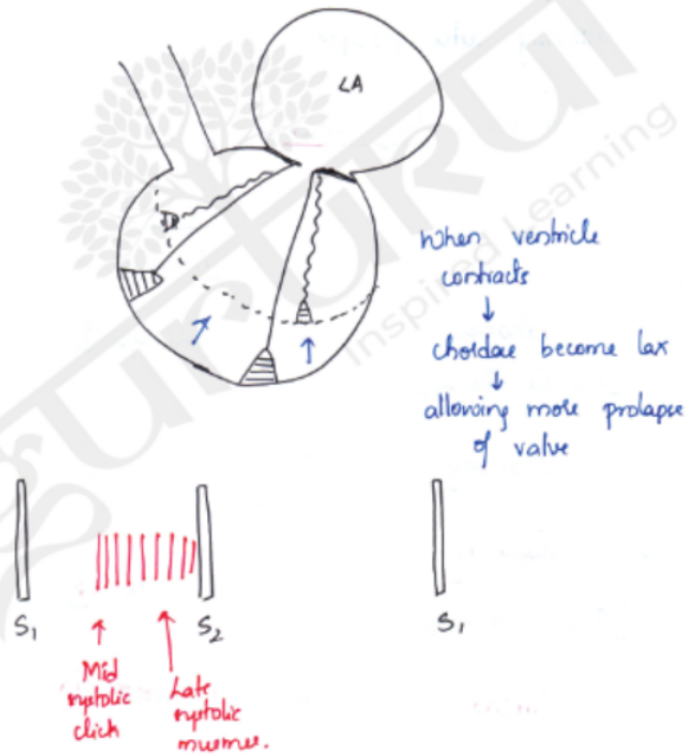

Telegram - @Latestpgnotes

2. MVP :

Lesser the blood → more is the murmur

↓

Endiastolic volume is less

↓

Chordae are lax.

↓

Allowing faster prolapse.

↓

↑ murmur & longer murmur.

		MVP Murmur	MR Murmur
• Valsalva [ventricle fills less]	-	Longer. ↑	↓
• Standing	-	Longer. ↑	↓
• Squatting [↑ venous filling]	-	Shorter. ↓	↑
• Supine.	-	Shorter ↓	↑

Telegram - @Latestpgnotes

	MVP murmur	MR murmur
Hand grip [↑ aortic pressure]	↓ [As blood is not pushed into aorta, ventricle is still filled with blood & chordae are tight]	↑ [As ventricles can't push blood into aorta, more blood goes into left atrium]

Secondary MR [functional MR]

Ischemic cardiomyopathy → Tethered posterior leaflet

Nonischemic dilated cardiomyopathy → Annulus is wide.

Valves not able to touch

↓

MR

Telegram - @Latestpgnotes

Following pdfs notes are available free →
1 → marrow edition 4 notes(latest optha notes also available) , marrow qbank , marrow pearls
2-> prepladder notes, prep rapid revision 2.0,prepladder treasures 3-> Notespaedia devesh mishra pathology notes, notespaedia marrow Ecg, Notespaedia elite optha
For more
4-> egurukul - - >aswini Kumar anatomy notes, dermatology notes, medicine by thameem sir, ortho notes, physio notes, radio notes(all by notespaedia)
5->all standards books and review books Telegram - @latestpgnotes
6->Notes on demand and many more premium notes are will available free very soon Telegram : @latestpgnotes For more latest notes, join the telegram channel @latestpgnotes
For neet pg discussions join telegram group @neetpgdiscussion
For more latest notes, join the telegram channel @latestpgnotes
Click on link below to join our telegram channel

For more latest notes, join the telegram channel @latestpgnotes For neet pg discussions join telegram group @neetpgdiscussion For group discount upto 40-50% on any lecture app or individual app dm @drnash1

Investigations:

- Echo:

Severity of MR:

Regurgitation fraction	> 50%
Regurgitation volume	>60ml
Vena contracta	>0.7 cm
Regurgitation orifice area	>0.4 cm^2
Jet area	>40%
LVESD	>40 mm

Vena contracta:

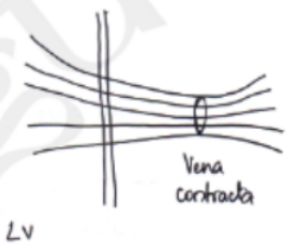

Narrowest portion before spreading of jet.

Telegram - @Latestpgnotes

- CXR :
  - Cardiomegaly
  - LA dilatation → 'Walking man sign' in lateral CXR.
  - Splaying of bronchi

℞ :

Symptomatic :

Ejection fraction > 30% ⇒ Surgical intervention [Mitral valve repair]

[EF < 30% → contraindication for surgery]

Asymptomatic :

LVESD > 40 mm
EF < 60%
Other echo findings of severe AR
A. fib
Pulm artery systolic pr > 50 mmHg
→ Mitral valve repair.

Secondary MR :
- CAD treatment
- Heart failure treatment.
- Consider CRT [Cardiac resynchronisation therapy]

Telegram - @Latestpgnotes

Alfieri Stitch

pulls the two leaflets together creating 2 orifices

↓ MR jet

- Percutaneous approach → Mitra clip.
- Caisson transcatheter mitral valve replacement
  - ↳ Valve in anchor.

Telegram - @Latestpgnotes

VHD – MITRAL STENOSIS

MC Cause – Rheumatic

↓

Valve inflammation, thickening

commissural fusion, calcification

⇓

'fish mouth' valve.

Causes :
- Rheumatic (90%)
- Calcific degenerative
- Congenital MS
- Atrial myxoma
- Endocarditis
- SLE / RA.

	Rheumatic	Congenital	Degenerative
Calcification	leaflets & commissures	Rare	Annulus towards leaflets
Commissures	Fused	Variable	usually free
Leaflet mobility	Restricted	Restricted	Tips are usually free

Telegram - @Latestpgnotes

Pathophysio

Mitral valve area (MVA) - 4-6 cm^2

↓

Progressive MS - MVA > 1.5 cm^2

* Severe MS - < 1.5 cm^2

Very severe MS (critical) - < 1.0 cm^2 or 0.6 cm^2/body surface area.

- LA enlargement
  ↓ over years
  LA pressure ↑

- As LV will recieve less blood
  ↳ Symptoms: • Exercise limitation
  • Fatigue

↑ HR - Anemia
Pregnancy
Thyrotoxicosis
Atrial fibrillation
Triggers

→ ↓ diastole
↓
∴ further ↓ filling of LV
↓
Symptoms

Telegram - @Latestpgnotes

- ↑LA pressure → Pulmonary edema
  - Dyspnea on exertion
  - Cough
  - Hemoptysis [Small bronchial veins]*

- Reflex vasoconstriction in pulmonary circuit ⇒ Pulmonary HTN
  - RVH
    - Right sided S_4.

- Pulmonary regurgitation – Graham steel murmur.
- In severe MS – tricuspid regurgitation.

★ LA enlargement → Left recurrent laryngeal nerve get compressed between LA & aorta
- Hoarseness [Cardiovocal syndrome]
- Ortner's syndrome

Telegram - @Latestpgnotes

ECG:

LA enlargement + RVH

Pathognomic to MS*

Summary:

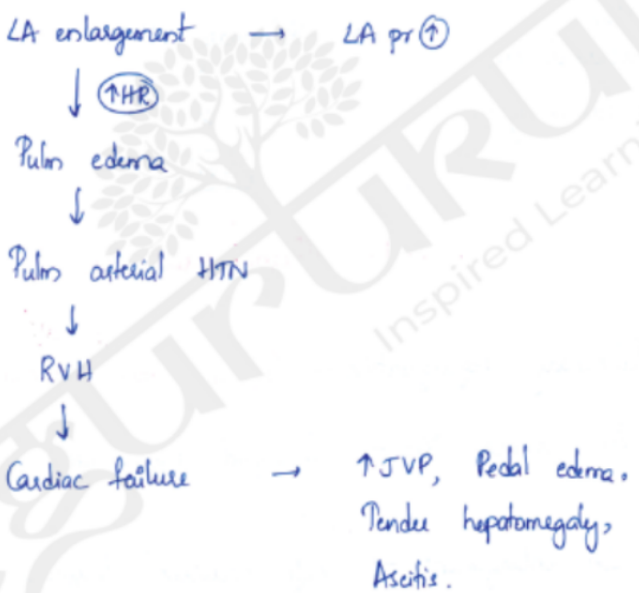

Telegram - @Latestpgnotes

O/E :

Pulse : • low volume
• Atrial fibrillation is more common
↳ irregularly irregular pulse.

JVP : Normal.

Absent 'a' – A. fibrillation
Giant 'a' – Pulm HTN
'cv' wave – TR.

Apical Impulse : Tapping in nature.
Diastolic thrill ±

Pulm area : Palpable P_2 [Pulm HTN]

Auscultation : Mitral area

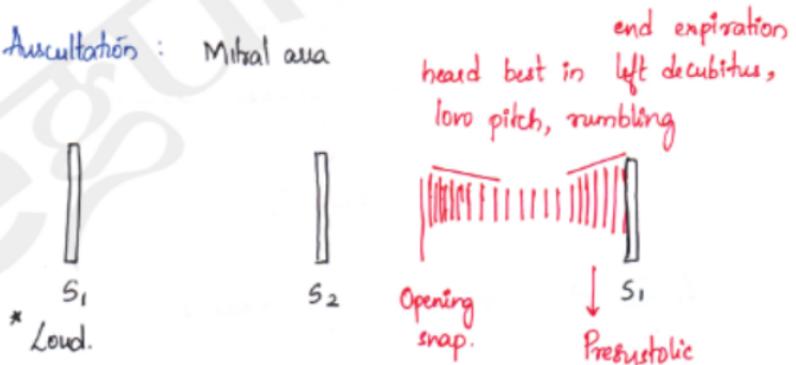

Telegram - @Latestpgnotes

Severe MS:

- Earlier Opening snap (OS)
- Longer the murmur.
- Shorter A_2 - OS gap.

Aortic / Pulmonary area:

P_2 - loud

Before Pulm HTN → Wide variable split.

[As less blood in LV & A_2 occurs early]

← A_2 P_2

Pulm HTN → Split becomes narrow

↓

Single S_2

A. fib → S_1 Intensity - variable.

Telegram - @Latestpgnotes

Carey coombs murmur : Acute rheumatic fever.

- Mid diastolic murmur.
- Soft
- S_1 - soft / Normal.

° ECG - LA enlargement + RVH. → R in V_1 + S in V_5/V_6 > 11 small boxes.

↓

- Broad notched P waves in lead II
- Broad negative P waves in V_1

° Xray :

LA enlargement - Straightening of left heart border
- Double shadow
- Push / Lifting of left main bronchus leading to splaying
- Main pulmonary artery - prominent
- Pulm edema - Reverse moustache sign
  Cephalisation of pulm. V.
  Kerley 'B' lines

Telegram - @Latestpgnotes

Images :

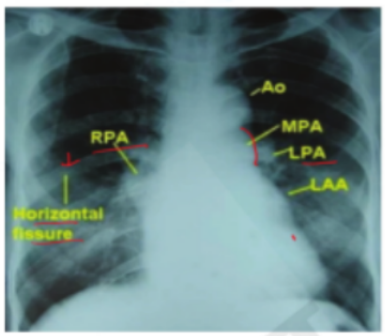

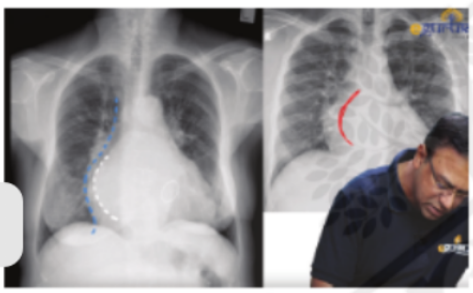

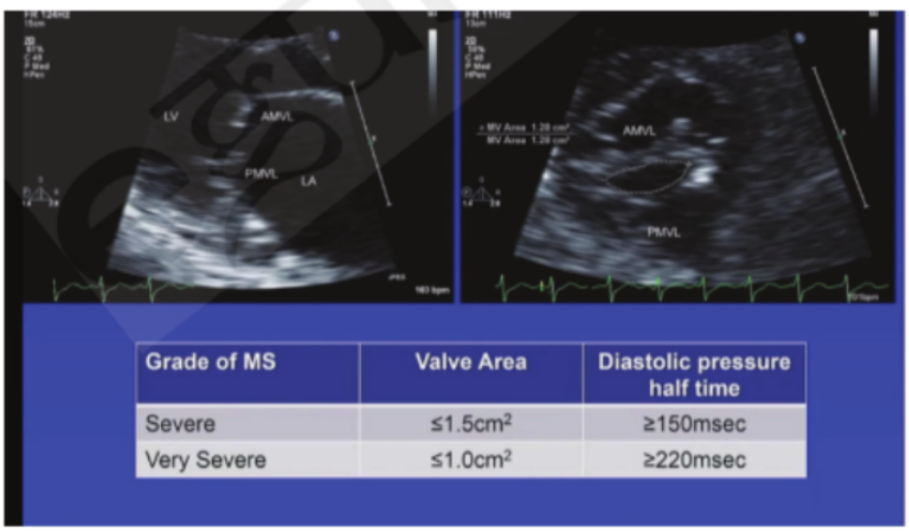

Grade of MS	Valve Area	Diastolic pressure half time
Severe	≤1.5cm²	≥150msec
Very Severe	≤1.0cm²	≥220msec

Telegram - @Latestpgnotes

Echo : . Hockey stick appearance of mitral valve due to doming.

· Enlarged LA.

℞ :

Percutaneous balloon mitral commissurotomy / valvuloplasty [PBMC]

↓

* Transesophageal echo is must prior PBMC

CI of PBMC :

- Left atrial thrombus
- Calcified annulus / commissures [left &] } Mitral valve replacement
- Combined MS & MR.

If patient is in A. fib :

↳ Patient should be on [Anticoagulation]

Warfarin** is used.

* Direct orally acting anticoagulants are contraindicated in mitral valve disease + Atrial fibrillation.

Telegram - @Latestpgnotes

Rx of A.fib c MS :

- Anticoagulants [Warfarin]
- β blockers
- Treat underlying triggers
- Diuretics [if pulm edema is ⊕]

- Critical MS [<1.0cm²] → Even if asymptomatic ⇒ Valvuloplasty*

- Severe MS [<1.5cm²] → Symptomatic ⇒ Valvuloplasty
  - → Asymptomatic
    - ↳ A. fib
    - ↳ Pulm HTN

    } ⇒ Valvuloplasty.

- Progressive MS [>1.5cm²] → Symptomatic on exercise. / Pulm HTN on exercise (>25mmHg) → Valvuloplasty

Telegram - @Latestpgnotes

25. ECG Part – 1.

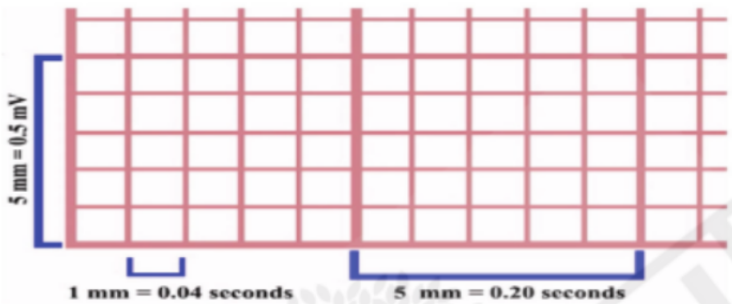

Speed → 25 mm/sec.

One Small Box → 1 mm = $\frac{1}{25}$ = 0.04 sec.

5 mm (5 Small Box) → 0.20 sec

1 mm = 0.1 mV



Telegram - @Latestpgnotes

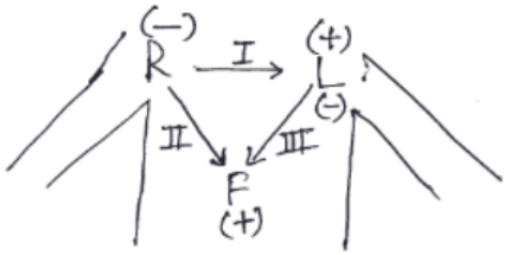

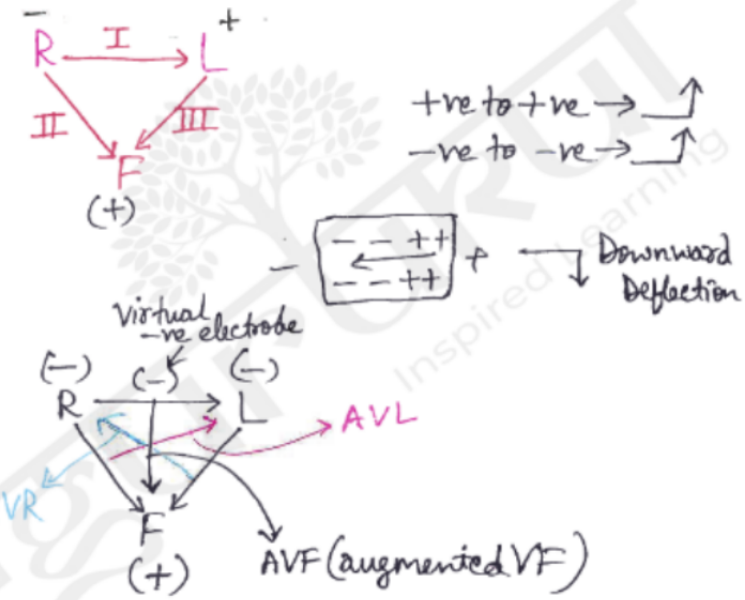

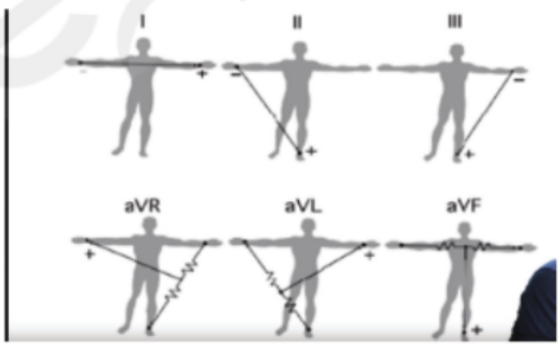

Telegram - @Latestpgnotes

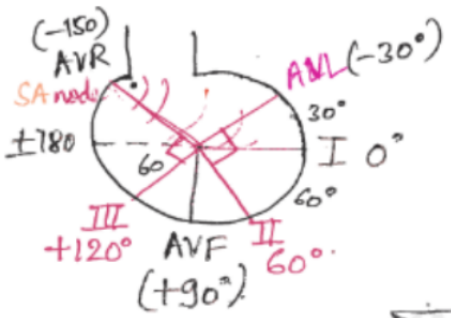

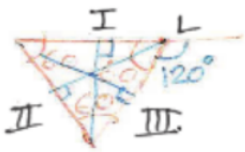

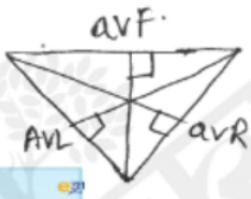

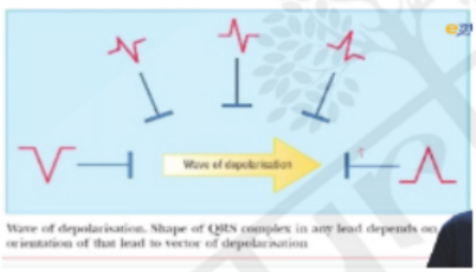

Wave of depolarisation. Shape of QRS complex in any lead depends on orientation of that lead to vector of depolarisation

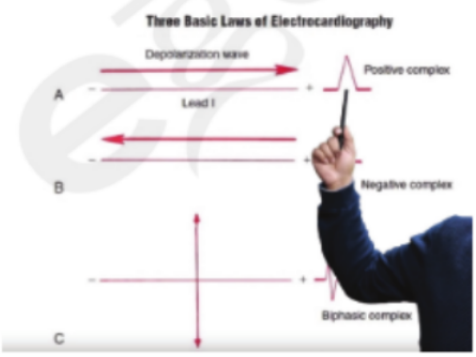

Telegram - @Latestpgnotes

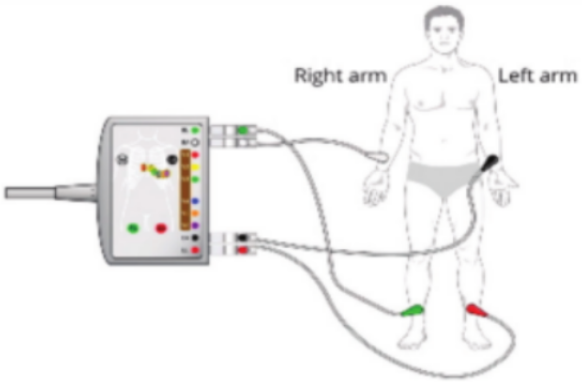

Black → (Lt) Arm
Red → (Lt) leg.

White → (Rt) Arm
(Rt) leg.
Green → (grounding)

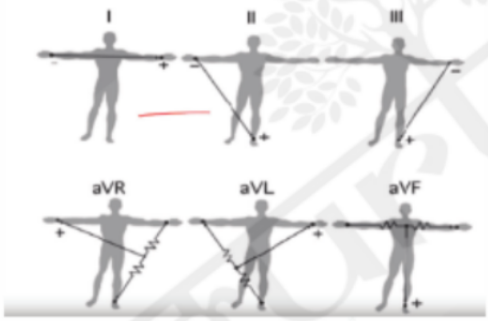

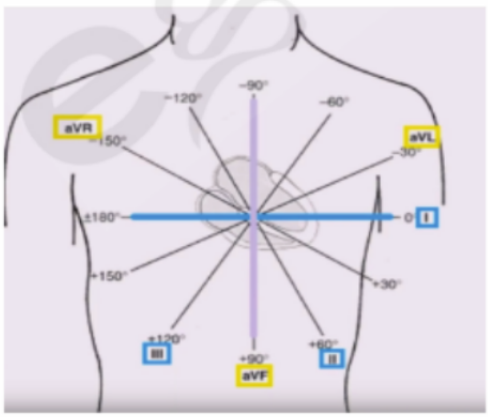

Telegram - @Latestpgnotes

$V_1 \rightarrow 4^{th}$ I.C.S to the (Rt)

$V_2 \rightarrow 4^{th}$ I.C.S to the (Lt)

$V_3 \rightarrow$ Exactly Midway b/w V_2 & V_4

$V_4 \rightarrow 5^{th}$ I.C.S. in Mid clavicular line

$V_5 \rightarrow$ Same Horizontal Plance as V_4 at Anterior Axillary line (V_5)

$V_6 \rightarrow$ Same Horizontal Plane as V_4 at Mid – Axillary line (V_5)

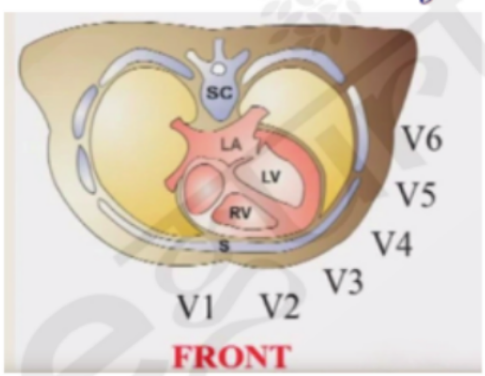

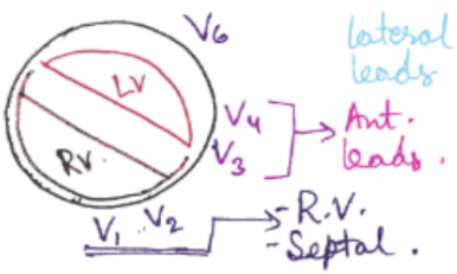

Telegram - @Latestpgnotes

- Frontal plane
- Horizontal Plane

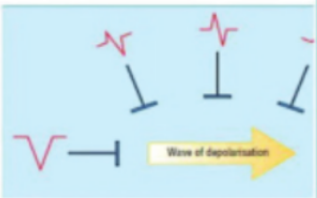

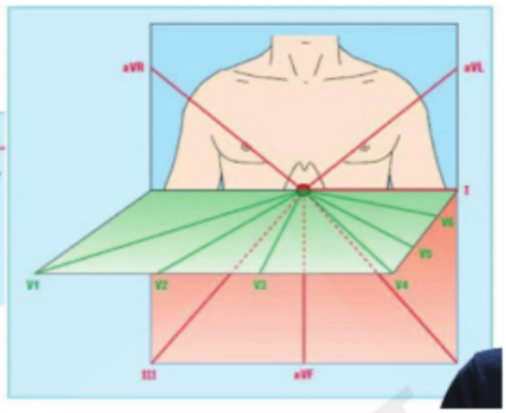

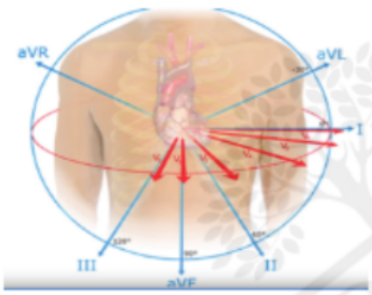

I, AVL, V5, V6 → Contigous leads

III, V1, V2 → RV leads

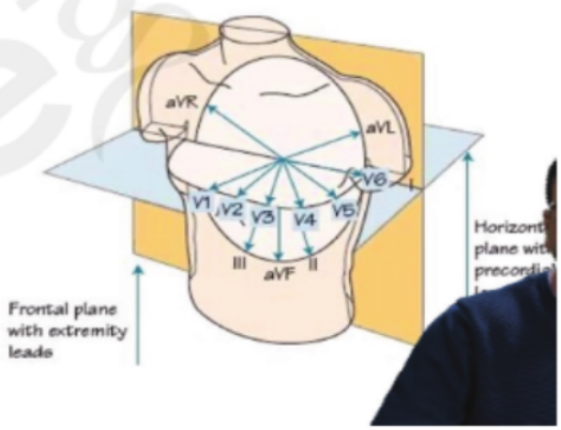

Telegram - @Latestpgnotes

26 ECG - Part 2



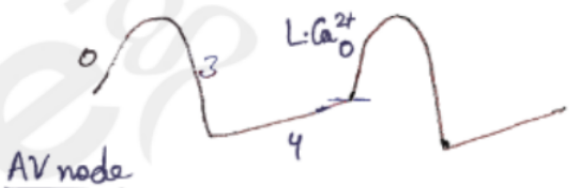

Telegram - @Latestpgnotes

Velocity of Conduction in Muscle : 0.5 m/s.

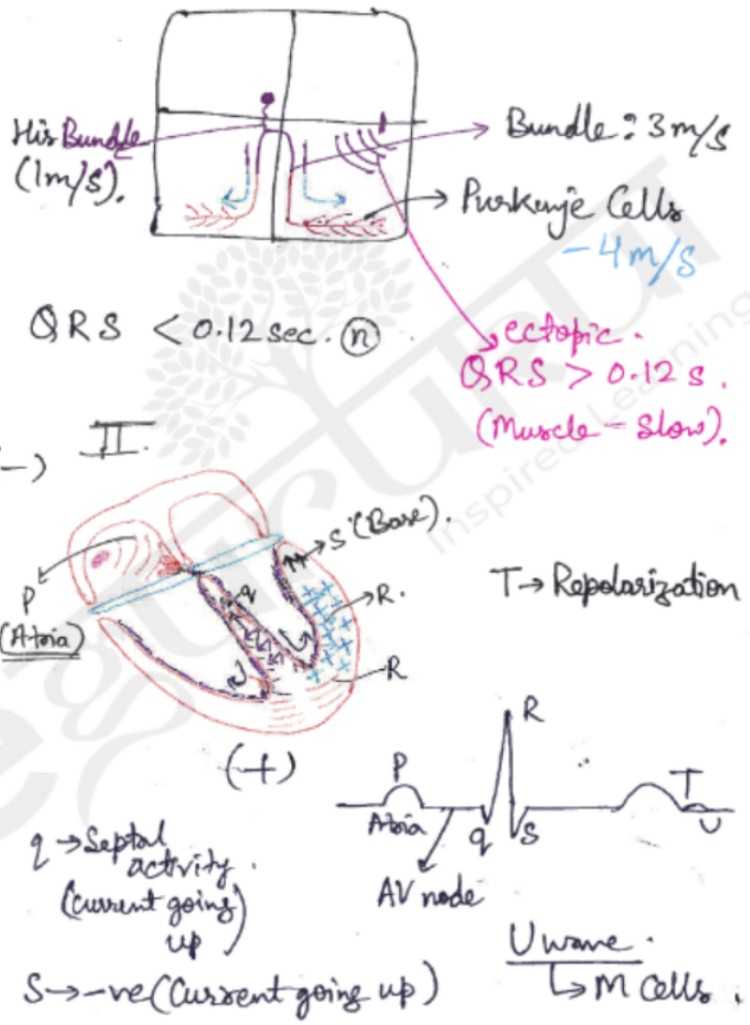

Telegram - @Latestpgnotes

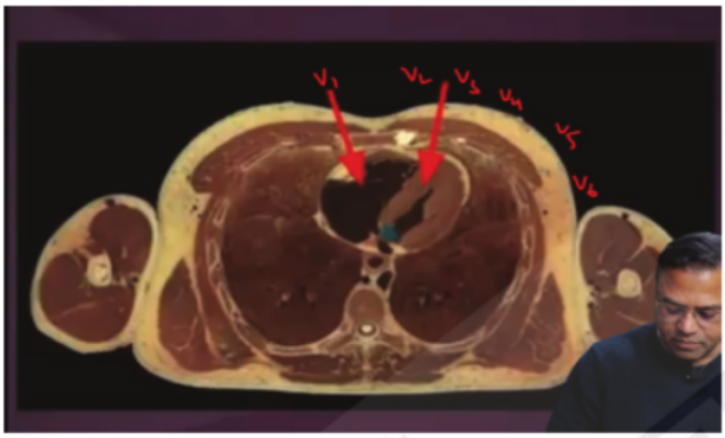

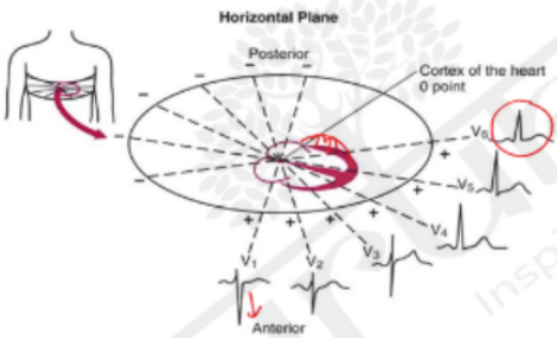

Placement of the precordial leads

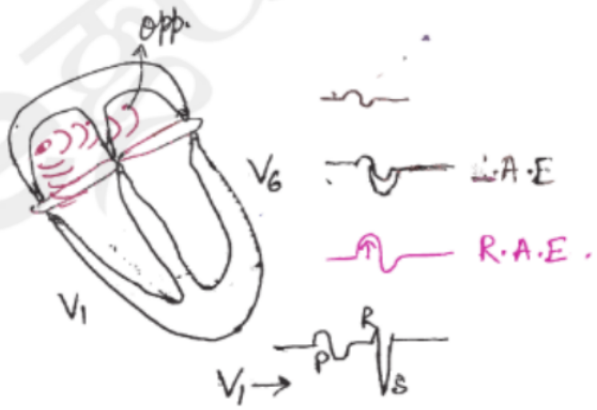

Telegram - @Latestpgnotes

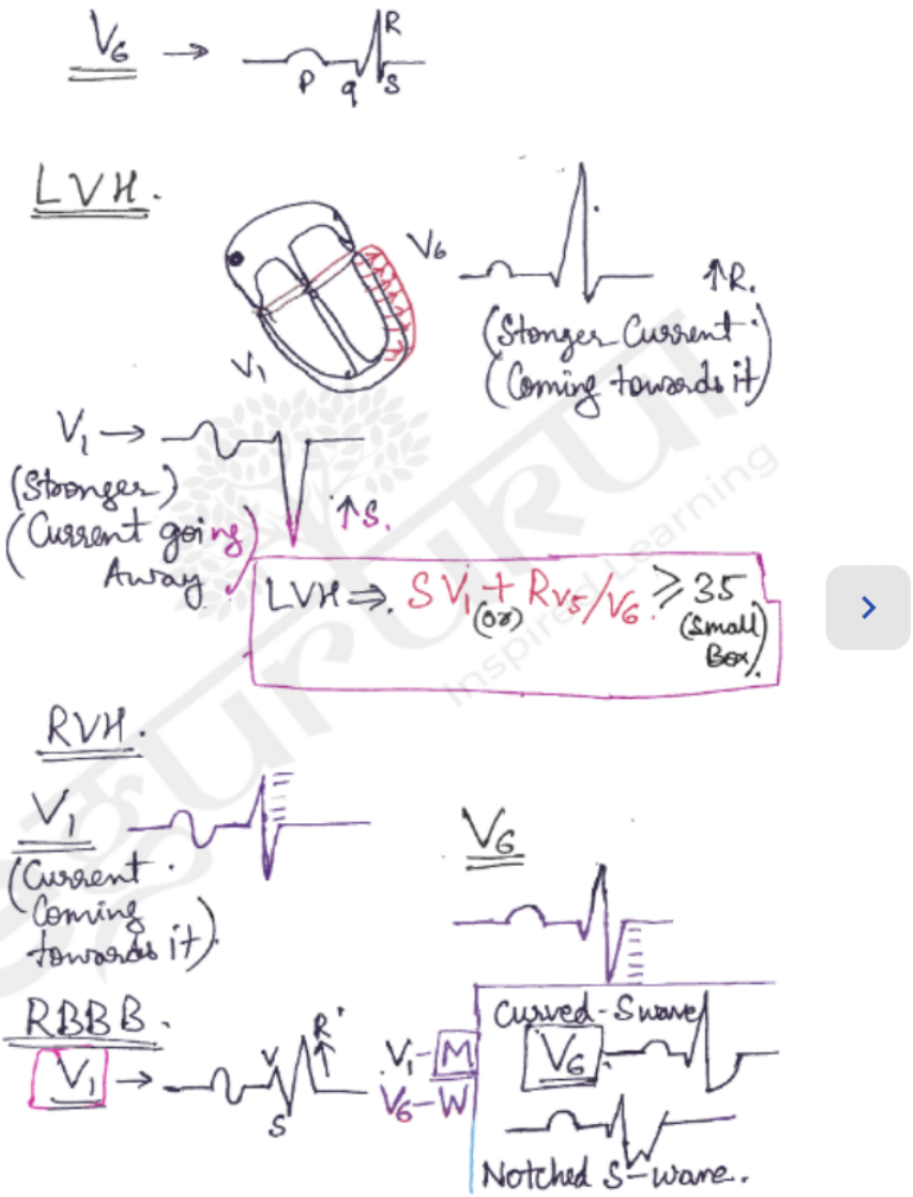

Telegram - @Latestpgnotes

V_6

→ Muscle : Strong Vector (LV).

V_1

opp. Side.

LBBB V_1 → (No R) V_6 (No q).

V → W

V_6 → M

LBBB.

(Big LV Activity)

V_1 V_6

WILLIAM.

MARROW

V_1 V_6

Telegram - @Latestpgnotes

28. ECG - Part - 3

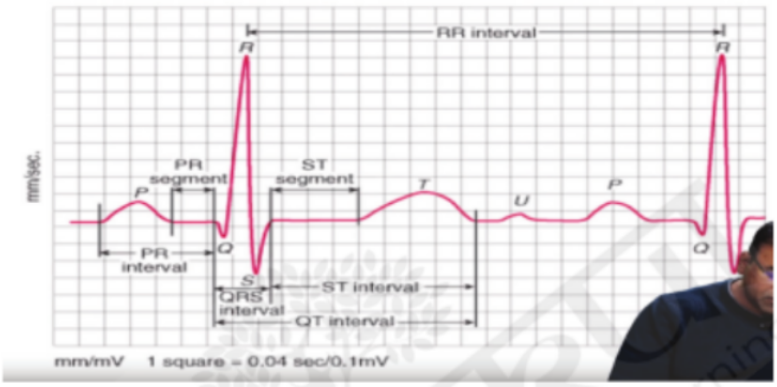

Starting of P to Starting of QRS → PR Interval
↓
P wave
+
(Flatline) PR Segment

J point to Starting of T → ST Segment

P wave → 2½ Small Box : ½ large Box
PR Segment → " "
QRS Width → " "

What is the heart rate?

Telegram - @Latestpgnotes

Heart Rate :-

$$- \frac{300}{\text{No. of large (RR) Boxes}} = \frac{300}{6} \Rightarrow 50$$

$$- \frac{1500}{\text{Small Boxes}}$$

1 large Box → 0.20 secs

P-wave

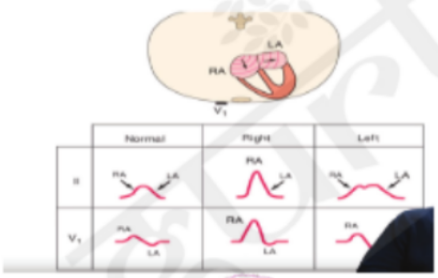

Telegram - @Latestpgnotes

L.A.E →

lead II → P – Broad P – mitrale.

PR Segment : Narrow.

P > 2½ Small Box in Height/width : Abnormal.

V_1 → R.A. L.A.

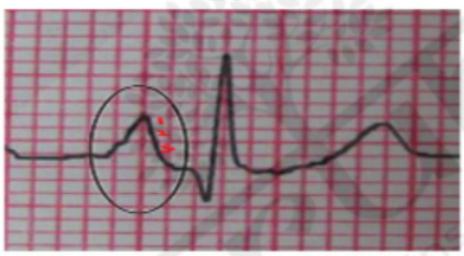

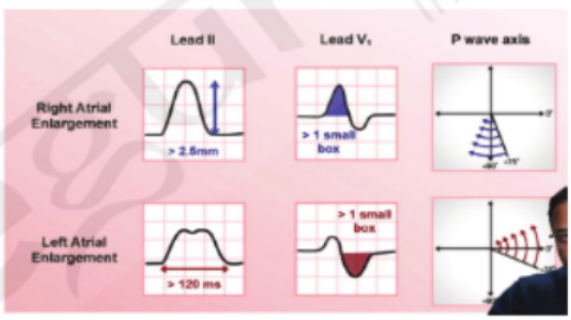

Morris Index : > 0.04 → L.A.E.

Depth of Terminal P wave (in mm) × Duration (in Sec)

Telegram - @Latestpgnotes

Macruz Index.

$$= \frac{\text{P wave Duration}}{\text{PR Segment}}$$

≥ 1.6 L.A.E.

RAE → Tall > 2.5 mm, Pointed P waves.
P- Pulmonale.

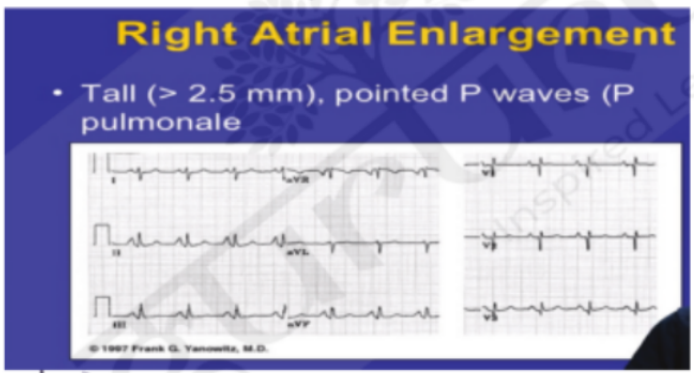

LAE → left Atrial Enlargement

→ Bifid P wave with $\boxed{> 0.04}$ secs between the 2 peaks.

→ Total P wave Duration > 110 ms or $\boxed{> 0.11 \text{ sec}}$.

In lead II

Telegram - @Latestpgnotes

In V_1

- Biphasic P wave with terminal negative portion > 40 ms (0.04 s) in duration.
- Biphasic P wave ± terminal negative portion > 1 mm deep

Left atrial enlargement

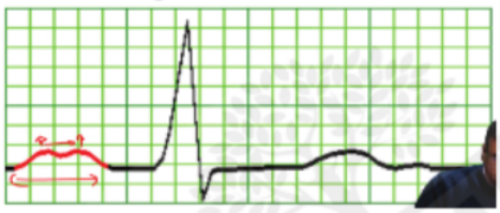

Telegram - @Latestpgnotes

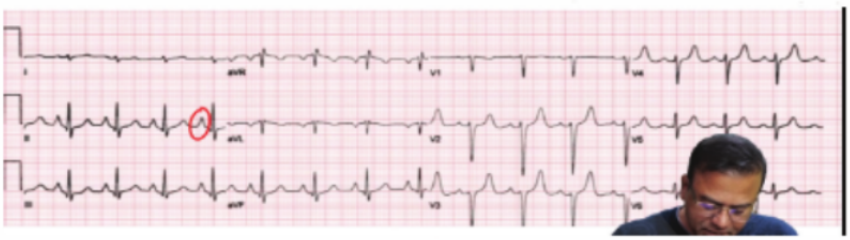

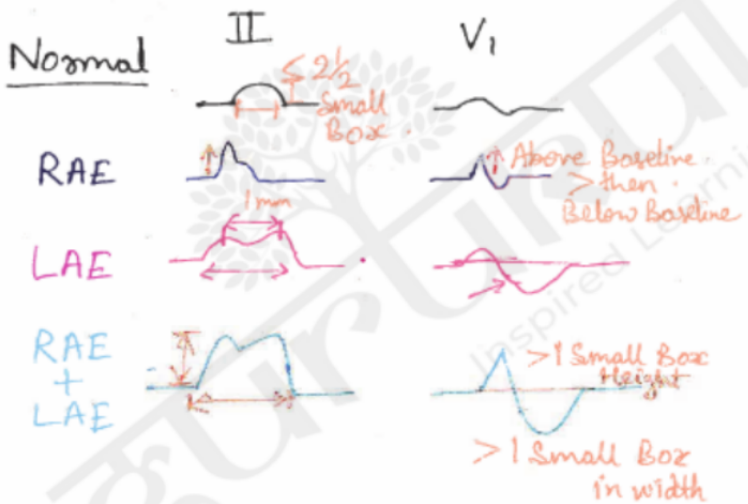

Q - wave → Septal Activity.

- Normal: < 25% of R in I, aVL, AVF, $V_{4,5,6}$.
- Pathological: $V_{2,3}$ > 0.02s (>1 Small Box).
  Other > 0.03s + > 1mm Deep.

J - Point → Point at which QRS gets over.

Telegram - @Latestpgnotes

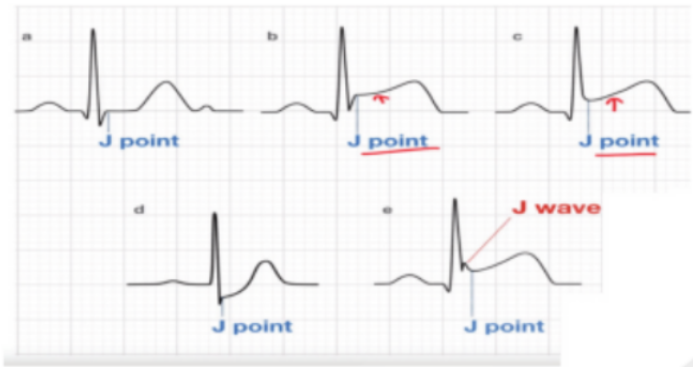

. J point elevation → ST elevation
J point Depression → ST Depression.

Hypothermia → Osbourne Wave.

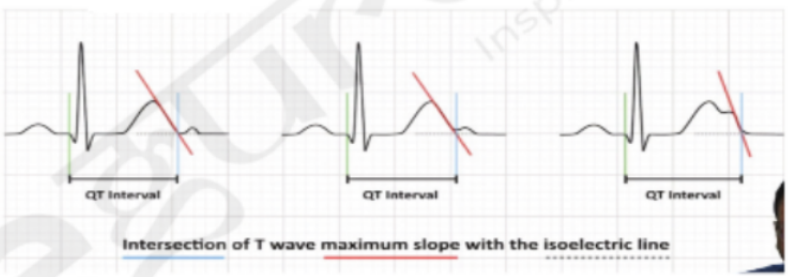

S-T Segment.

ST-elevation Causes :- ST-elevation MI.
LBBB.
LVH

Telegram - @Latestpgnotes

ST↑ → • (N) variant.
(a.k.a Early Repolarization) Synd.
• Pericarditis (only ST↑).
• LV aneurysm (Persistent ST↑)
(Prizmental Angina) → Vasospasm (Cocaine Abuse).
• Severe Hyperkalemia.
• Hypothermia.
• Brugada Syndrome

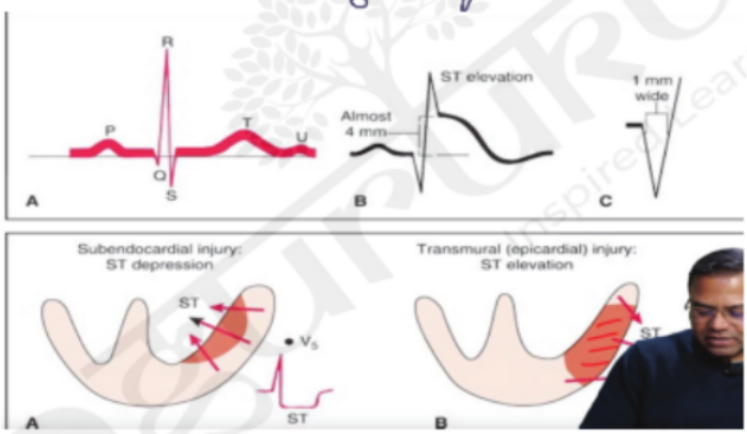

Transmural Infraction :- ST↑
Subendocardial MI :- ST↓
Ischemia/Angina

Convex upward.
Concave Downward.

Telegram - @Latestpgnotes

Early Repolarisation ·

- Concave ST elevation ·
- Notched, Slurred or otherwise well Demarcated J-point ·

Pericarditis →

- Concave ST elevation ·
- PR depression ·
- ST/T ratio >25%.



LBBB ·

Hyperkalemia ·

- ST-Segment pulled by T-wave ·
- T-tall & narrow ·
  (not wide as in STEMI.

Telegram - @Latestpgnotes

Early Repolarisation ·

- Concave ST elevation ·
- Notched, Slurred or otherwise well Demarcated J-point ·

Pericarditis →

- Concave ST elevation ·
- PR depression ·
- ST/T ratio >25%.



LBBB ·

Hyperkalemia ·

- ST-Segment pulled by T-wave ·
- T-tall & narrow ·
  (not wide as in STEMI.

Telegram - @Latestpgnotes

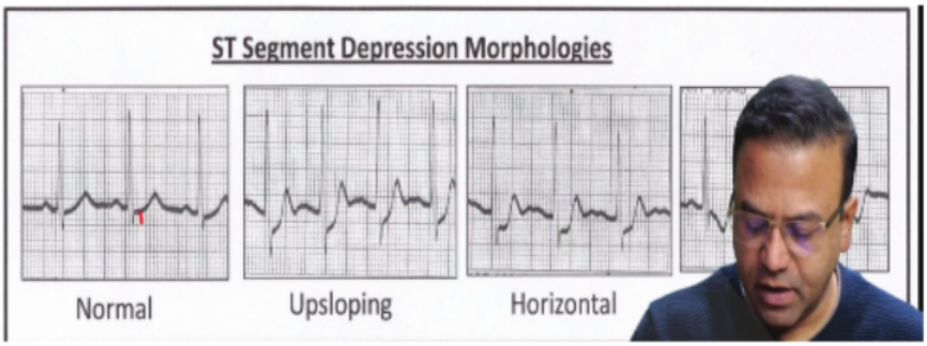

ST↓ >0.5mm (Half Small Box).
→ 0.08 secs after J point. (ST80)
[(>2 Small Box after J point (Width) ST Depression is checked).]

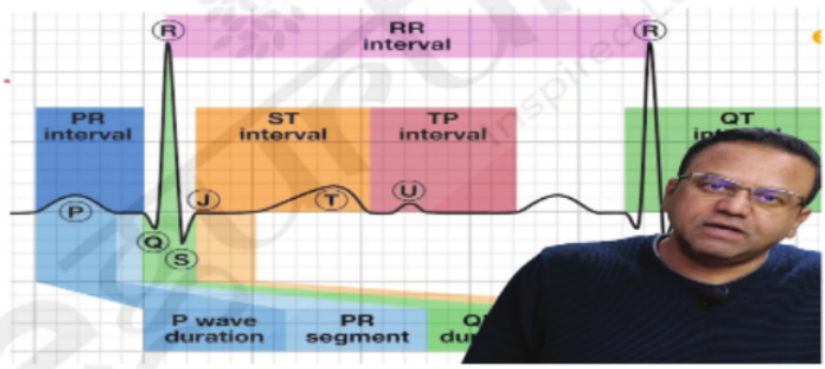

T-Wave

Normal T wave
Smooth transition from ST-segment to T wave. T wave is slightly asymmetric with a steeper downslope.

Normal variant
Large, asymmetric T wave with broad base. Often in conjunction with slight J point elevation in leads V2-V4.

Hyperkalemia
Large, symmetric, pointed with short base.

Telegram - @Latestpgnotes

- Hyperkalemia : large Symmetric. Pointed & Short Base
- Hyperacute T-wave : Blunt.
  - → M.I.

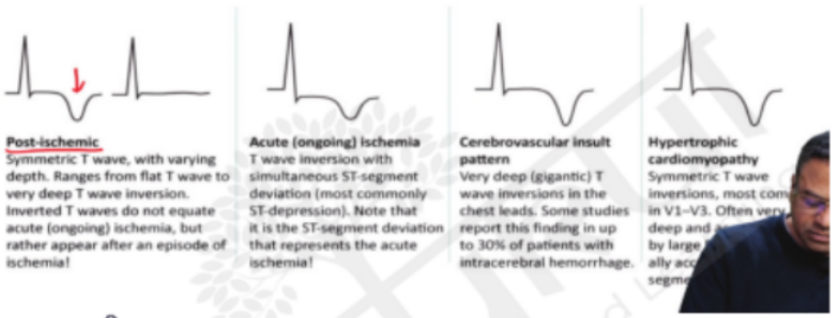

- Post Ischemic → Symmetric T-wave inversions.
  - Flat T wave.
  - → very Deep T waves.
- Acute On going Ischemia
  - T wave Inversion & ST deviation
- Cerebrovascular Insult Pattern.
  - Very Deep (Gigantic) T wave inversion
- Hypertrophic Cardiomyopathy.
  - Symmetric T-wave inversions (V_1–V_3)

Telegram - @Latestpgnotes

T- wave :- Repolarisation.

F. (n) . ↳ Epicardium to Endocardium

Depolarisation.

Thickness ↑.

LVH.

Repolarisation.

Endo to Epi :- T-wave Inversion

Prolonged Muscle Conduction.

Left bundle branch block (lead V6)

Left ventricular hypertrophy (lead V6)

Right bundle branch block (lead V1)

Pre-excitation (delta wave)

Right ventricular hypertrop

Large R-waves and ST-segg depressions in V1–V3. In ca chest discomfort, one consider pos lateral tran differenti

Telegram - @Latestpgnotes

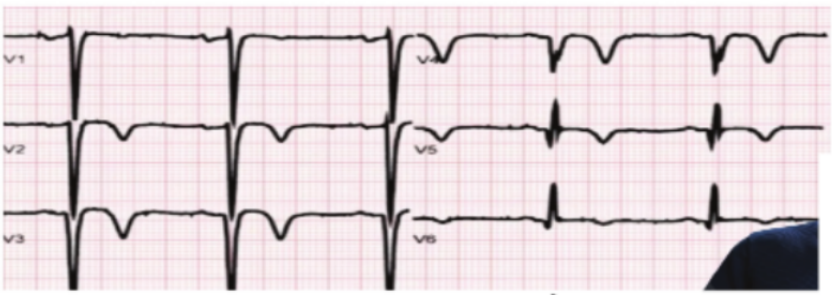

(52:46) Wellen's Synd. (Biphasic).
↳ LAD~~#~~

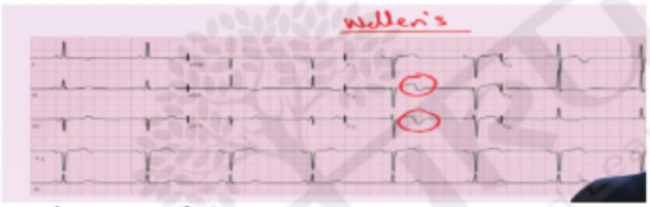

(53:26) → Inverted Tick Mark : Digoxin Effect.

Effects on ST Segment and T wave

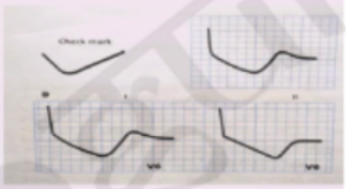

(54:57) Salvador Dali Sign (↻)

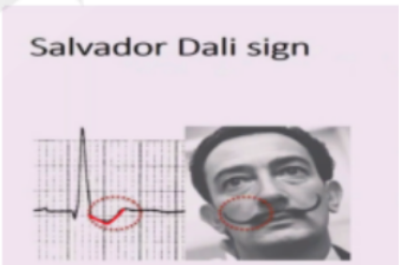

Telegram - @Latestpgnotes

QT- Interval

- Total Duration of Ventricular electrical Activity.



QT Interval $\propto \frac{1}{\text{Heart Rate}}$.

Long QT → QT_c > 0.46 (460)

Short QT → QT_c < .36 (360)

(n) QT = ½ RR Interval. If (n) H.R.

Prolonged > ½ RR.

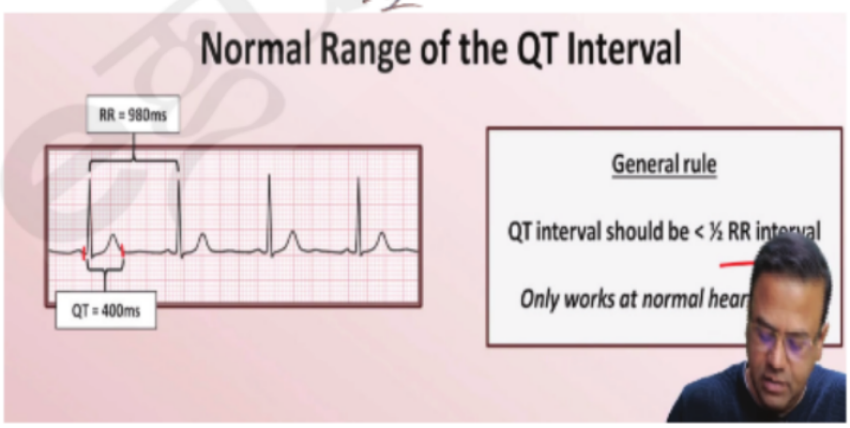

Telegram - @Latestpgnotes

QT Interval : Bazett's Formula.

$$QT_c = \frac{QT\ (ms)}{\sqrt{RR}\ .\ (RR \text{ measured in Seconds})}$$

JT Interval.

$$JT_c = \frac{JT\ (ms)}{\sqrt{RR}.(s)}$$

Congenital Long QT Syndrome (LQTS).

- Romano - Ward : Long QT without Deafness
- Jervell & Lange - Nielsen.
  ↳ long QT + Deafness.

LQTS → Type 1 :- Swimming . K^+ #
Type 2 :- Emotional Stress K^+ #
Type 3 :- Sleep → Na^+ # (Rare).

Polymorphic VT

R_x → β- Blockers .

Drugs Causing QT - Prolongation

Class III Antiarrhythmics

Telegram - @Latestpgnotes

Class III Antiarrhythmics → ↑QT (High Risk).
↓.
- Amiodarone.
- Sotalol.
- Ibutilide.

Anti Psychotics
- Thioridazine.
- Ziprasidone.

Class Ia Antiarrhythmics
- Quinidine.
- Procainamide.

Others → Cisapride

Moderate Risk..

Antipsychotics → All others.

Antiemetics → Ondansetron.
Metoclopramide.

Antidepressant → TCA's.
SSRI's.

Antibiotics → Quinolones.
Macrolides

Other → Methadone.

Telegram - @Latestpgnotes

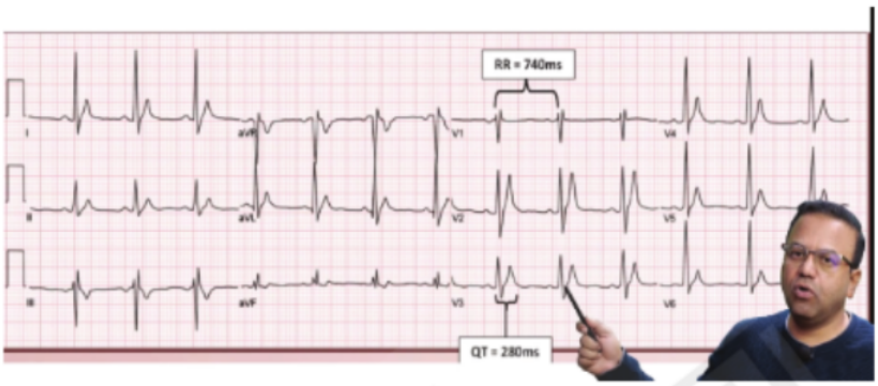

29. ECG - PART - 4.

Ventricular Hypertrophy.

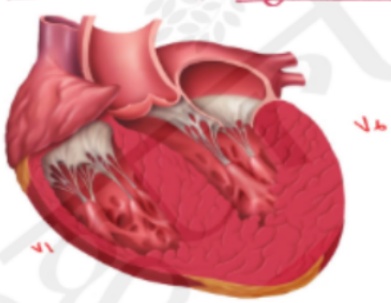

Preload → Amount of Blood present in Ventricles before it Pumps the Blood out.

Afterload → Effort taken to Push Blood out.

Telegram - @Latestpgnotes

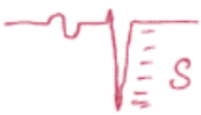

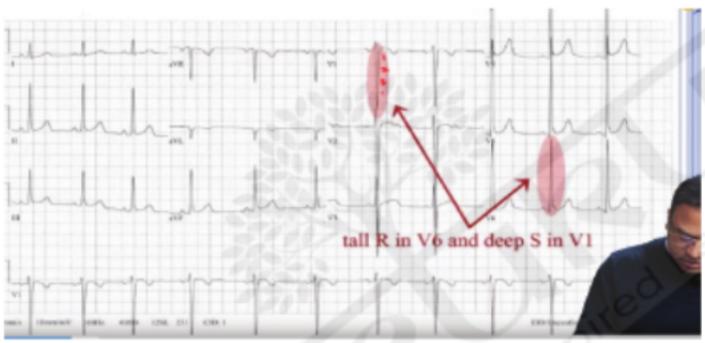

Sokolow – Lyon Criteria

S-wave in V_1 + R wave in V_5 or $V_6 \geq 3.5$ mV (35 mm)

or

R wave in V_5 or $V_6 > 2.6$ mV (26 mm)

Romhilt Estes Criteria (Best).

Sin V_1 or $V_2 \geq 30$ mm — 3.

Rin V_5 or $V_6 \geq 30$ mm

ST depression — 3.

(+) Atrial Enlarge → 3.

Telegram - @Latestpgnotes

QRS duration ≥ 90ms
(+) Axis deviation — 2
Intrinsicoid deflection
in $V_5 - V_6 \geq 50$ms — 1

4 Points : Probable LVH
5 Points : Definite LVH

Simplified Criteria for Δ^{SIS} of LVH ☆

- Deepest S wave in lead V_1 or V_2
  +
  Tallest R wave in lead V_5 or V_6 ≥ 35
  Small Box
- Patients ≥ 35 yr old
- (+) Ventricular "Stair" → T wave Inversion

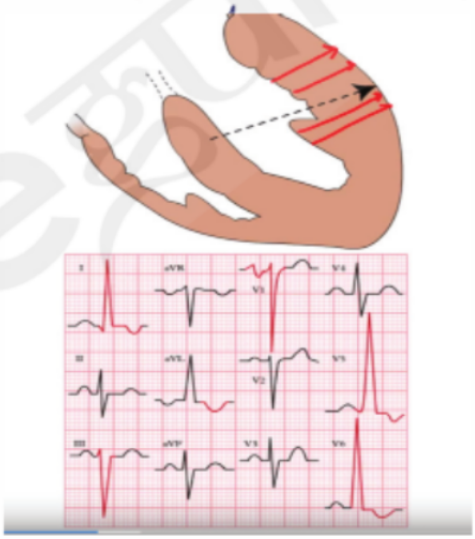

Telegram - @Latestpgnotes

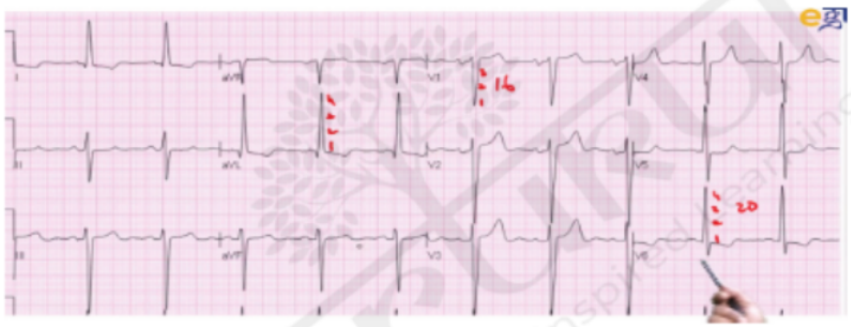

Right Ventricle Hypertrophy.

- Sokolov - Lyon Criteria:

  R in V_1 + S in V_5 – V_6 > 11mm.

  R in V_1 > 7 mm.

  R : S in V_1 > 1

  RAD > + 90 degree.

Telegram - @Latestpgnotes

Additional Criteria.

- QR in V_1
- $S_1 Q_3$ Pattern.
- P Pulmonale.

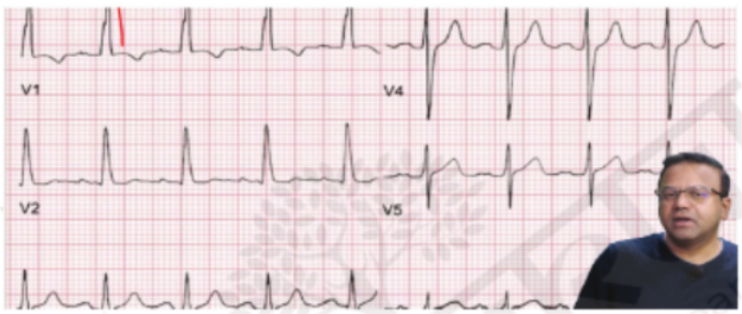

(18:10) R wave in V_1, S in V_6.

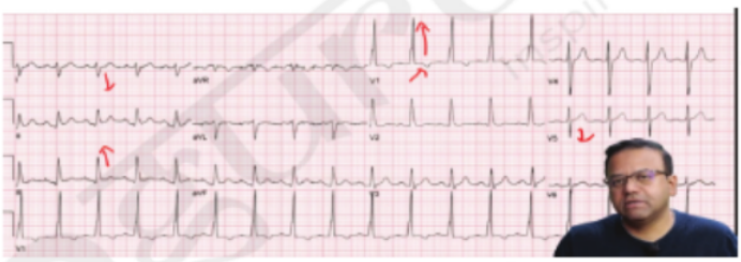

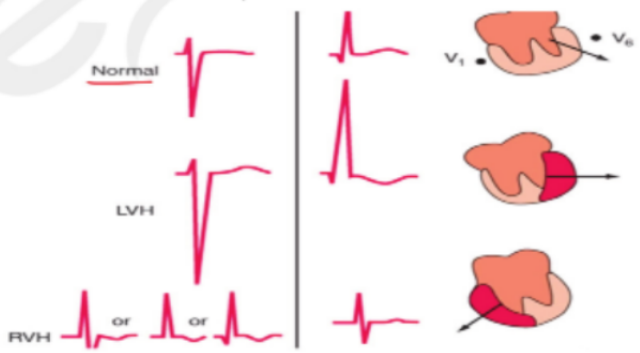

Telegram - @Latestpgnotes

Low Voltages - ($V_1+V_2+V_3 < 15$)

Low Voltage ECG.

Cardiac.
(Voltage Generation)

- Infiltrative Cardiomyopathy
  - Hemochromatosis
  - Sarcoid
  - Amyloid.
- ACS.
  → large MI or Multiple MI (+)
- Myocarditis
- Hypothyroidism (Myxedema)
- Constrictive Pericarditis.

Dampening effect.

- Soft tissue.
  → Obesity.
  - Edema.
- Fluid.
  - Pericardial effusion.
  - Pleural effusion.
  - Pul. edema.
- Air.
  - COPD.
  - Pneumothorax
  - Pneumomediastinum
  - Pneumopericardium

Telegram - @Latestpgnotes

Pericardial effusion :- Electrical Alterans.
(Varible R-waves)

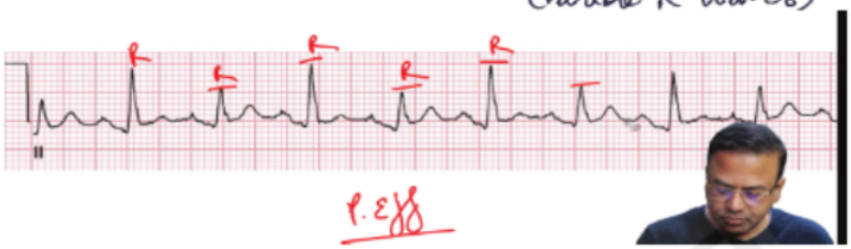

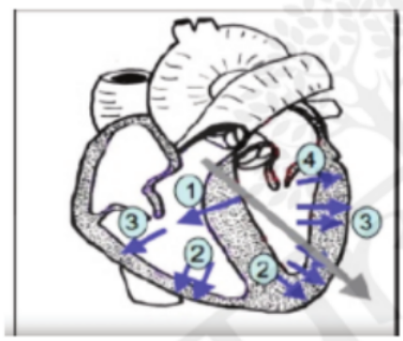

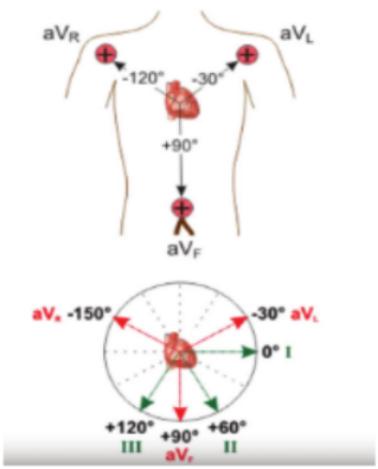

Telegram - @Latestpgnotes

Left Axis Deviation → −30° to −90°

Right Axis Deviation → +90° to 180°

Nort-west (extreme) axis → −90° to 180°

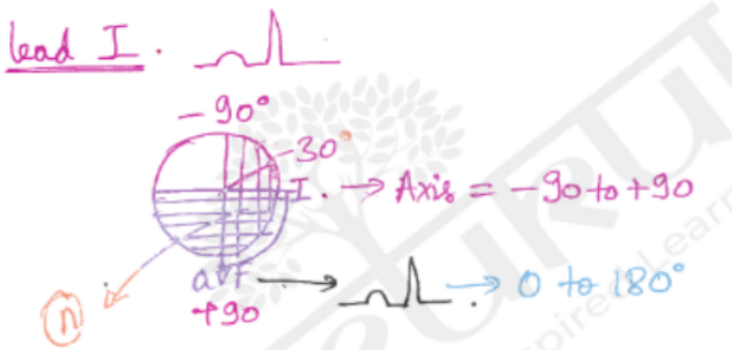



avR →

= R − (S) − (S)

→ +ve : Upward Deflection

→ −ve : Doward Deflection

Telegram - @Latestpgnotes

(N) Axis -

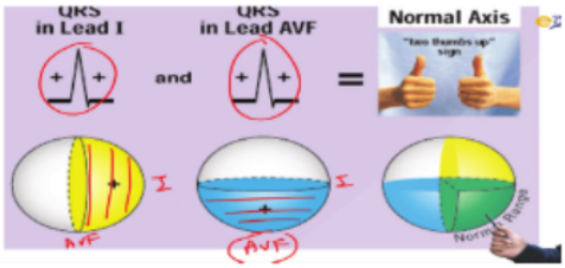

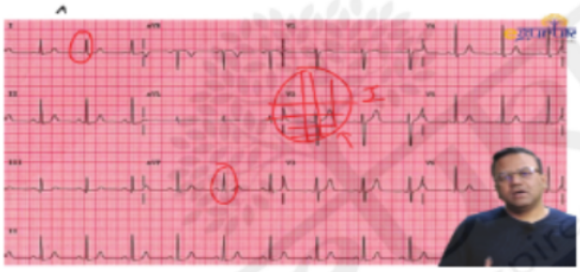

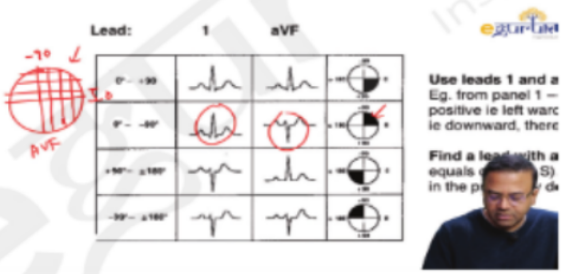

lead I → ↓.
aV F → ↑
Right Axis Deviation
(+90 – ±180)

lead I → ↑
aVF ↔ ↓.
(L) Axis Deviation.
(0 to -90°)

Telegram - @Latestpgnotes

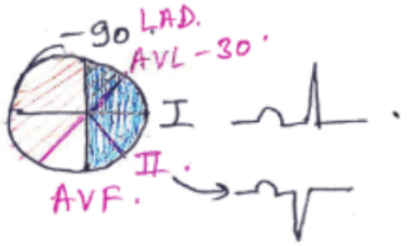

LAD → lead II has to be Dowards deflection

RAD

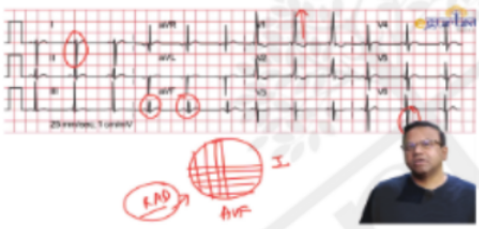

LAD.

Telegram - @Latestpgnotes

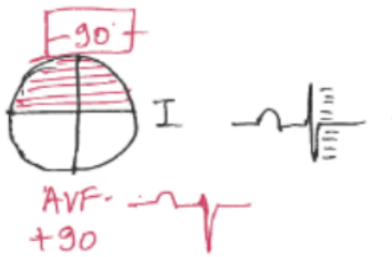

R-S-Q = 0.
(Biphasic)

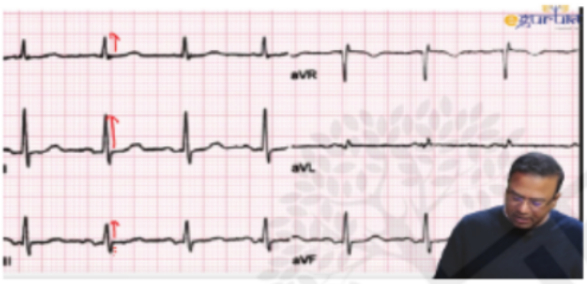

Indeterminant Axis → COPD

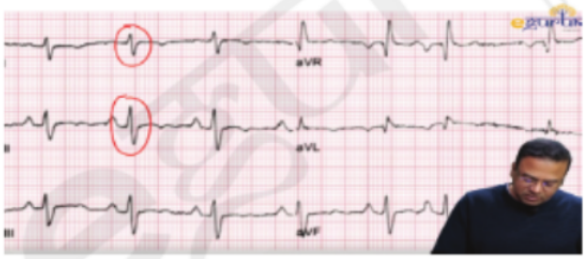



I
aVF

R-S-Q = +6

" = -7.

Telegram - @Latestpgnotes

30 CARDIAC ARRYTHMIAS-1

Arrhythmias : Reasons

→ ↑ Automaticity.

→ Re-entry.

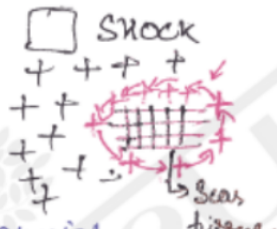

Max H.R. → 220 − Age.

More than Maximum: Arrhythmias.



Atrial Fibrillation

Source

Telegram - @Latestpgnotes

Atrial Rate → 350 – 600

Ventricular Rate → 160–200

Symptoms worse

AV node blocks most ↑ Refractory Period. ≤ 150

Pulse → Irregularly Irregular.

JVP → "a" Absent.

ECG → Fluctuating RR interval.

Causes →
- HTN.
- Ischemic H.D
- Valvular (Mitral).
- Idiopathic.
- Alcohol: Holiday Heart Syndrome
- Thyrotoxicosis / Pheochromocytoma.

Telegram - @Latestpgnotes

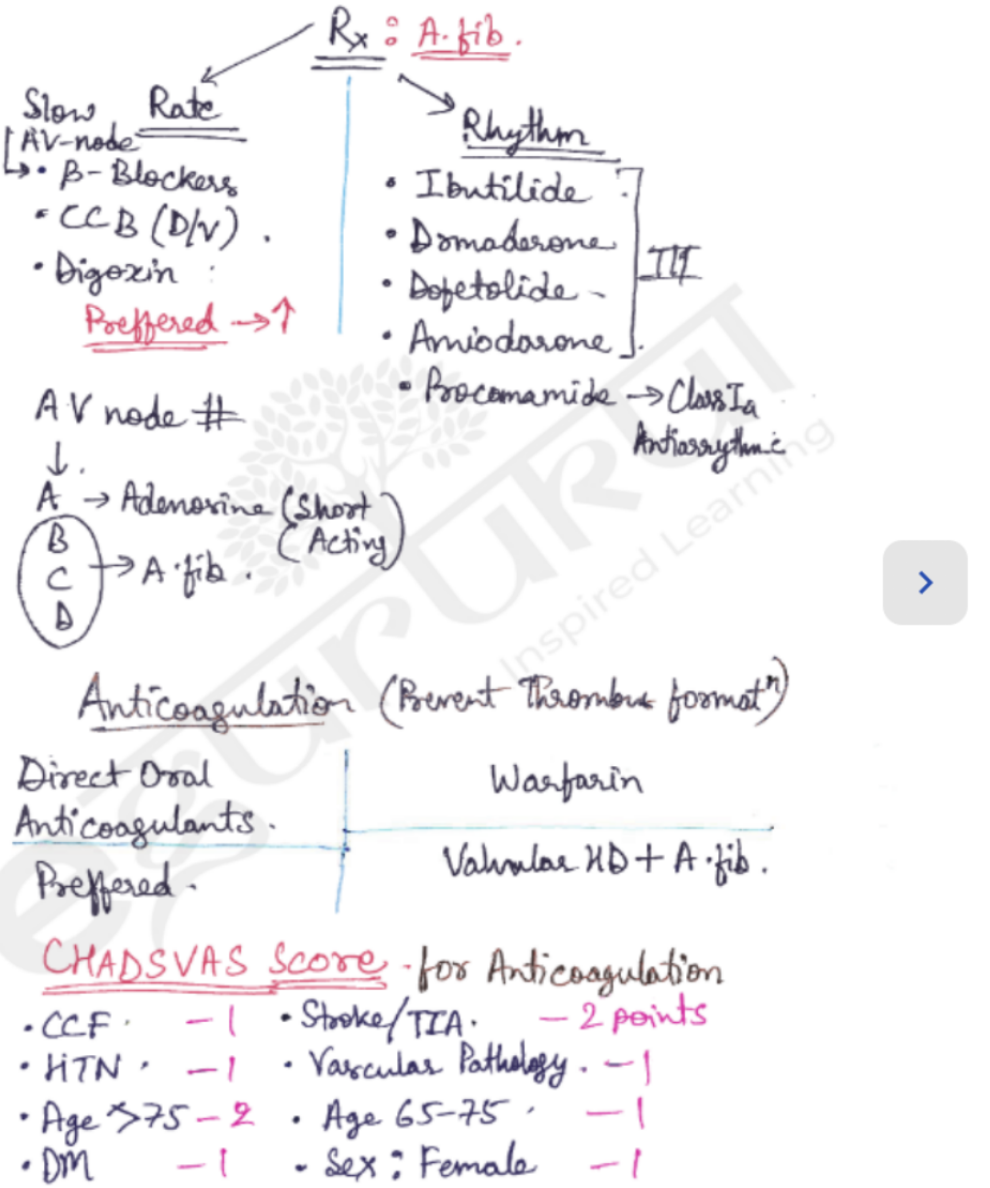

CHADSVAS Score - for Anticoagulation

- CCF. — 1
- HTN. — 1
- Age >75 — 2
- DM — 1
- Stroke/TIA. — 2 points
- Vascular Pathology. — 1
- Age 65–75. — 1
- Sex : Female — 1

Telegram - @Latestpgnotes

≥ 2 for male .
or ≥ 3 for Females] Anticoagulants

HAS-BLED Score (evaluation of Bleeding Risk)

	Points
Hypertension .	1
Abn (1) Liver & Renal function (1 pt. each)	1 or 2 .
Stroke .	1
Bleeding .	1
labile INR	1
Elderly (e.g. Age >65yrs)	1
Drugs or Alcohol (1 pt. each)	1 or 2
	Max. 9 points

≥3 → Caution against Anticoagulation .

(36:38) Multifocal Atrial Tachycardia .

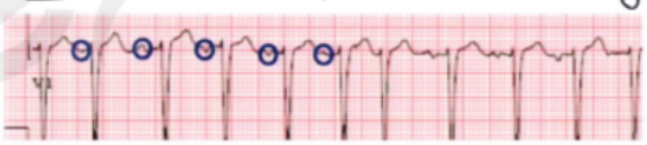

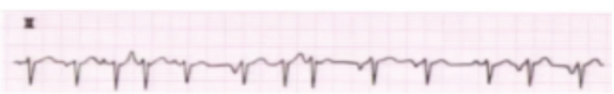

Telegram - @Latestpgnotes

An 85 y/o man with Severe Emphysema is Admitted to the medical ICU due to. Acute Shortness of Breath and Tachycardia His Pulse is irregular : you Perform an ECG.

COPD → : MAT

Atrial Flutter : (RT) Atrium

Single Macro (large) Re-entry Tract

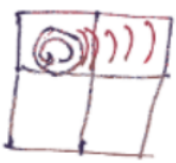

Inverted P wave [II, III, aVF (Inf. leads)]

Telegram - @Latestpgnotes

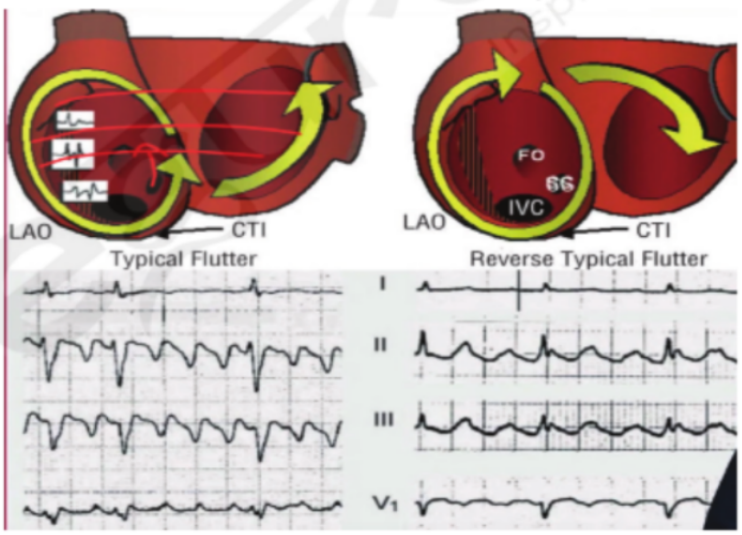

Telegram - @Latestpgnotes

31. CARDIAC ARRYTHMIAS – 2

SVT : Commonly occurs in Paroxysms : PSVT

Mechanism →

- AVNRT (AV – nodal Re – Entry Tachycardia)
- AVRT (Atrioventricular Re – Entry Tachycardia)
  - ↳ Requires Accessory Pathway.

AVNRT (More Common)

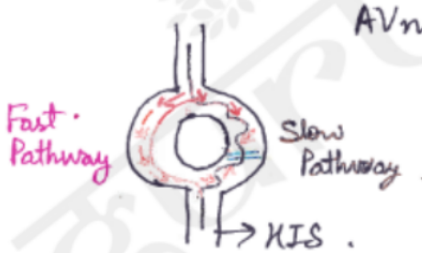

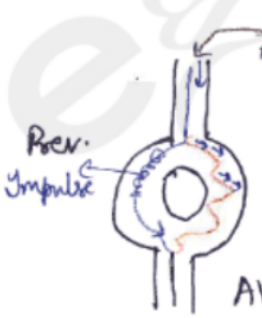

→ Retro-Inverted P-waves

P-wave :- Inverted .
Retro (after QRS)

AV nod ~~Supply~~ → Atria (opp. Current)

Telegram - @Latestpgnotes

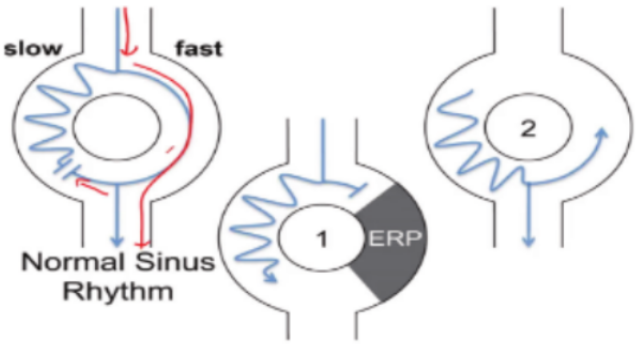

RR interval is equal (A-fib : fluctuating).

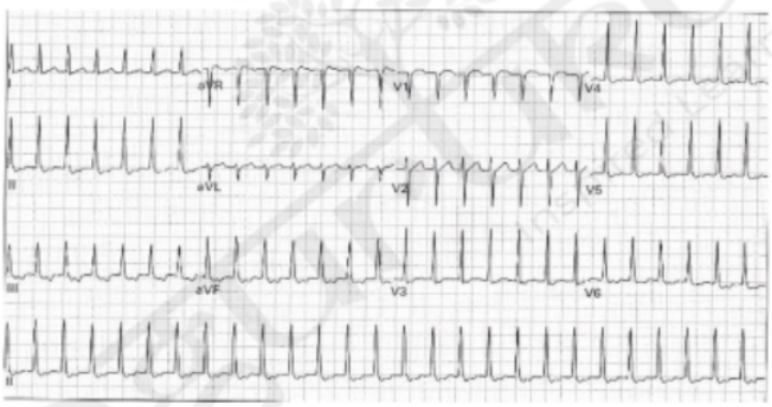

When Ventricular Rate is ≥ 150

↓

→ Rule out Atrial flutter.
– Rule out A. fib.

Telegram - @Latestpgnotes

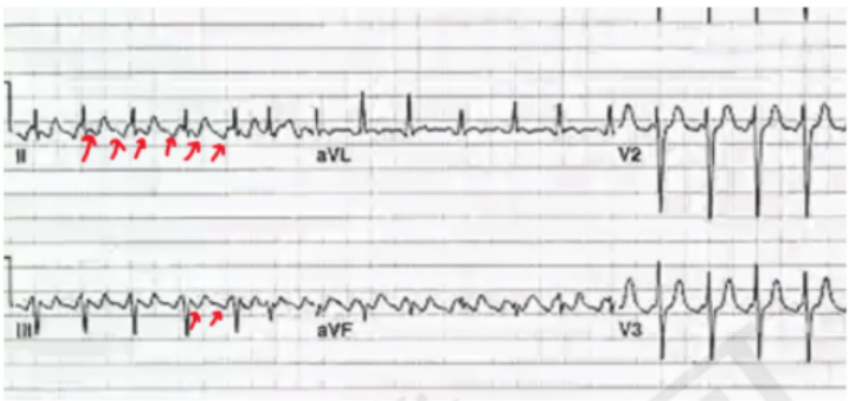

Rx → 1st → Vagal Manoeuvre.

↓

Carotid massage.

↓

Adenosine → I.V. 6mg.

↓

- β-Blockers
- CCB.
- Digoxin

WPW → Accessory Pathway ⊕

- Short-PR.

Telegram - @Latestpgnotes

Short PR.
QRS > 0.12secs.
δ waves
] WPW

WPW — Type A → LA to LA (More Common)
→ Type B → RA to RV.

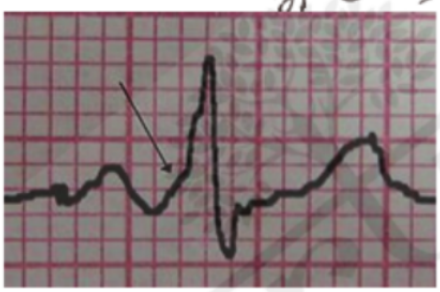

Telegram - @Latestpgnotes

Rx → Ablation of Accessory Pathway.

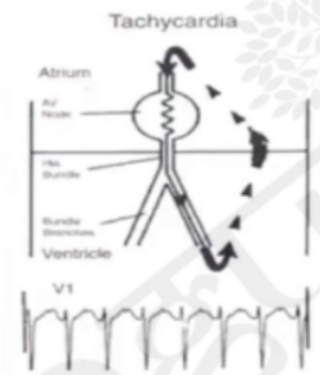

Telegram - @Latestpgnotes

(38:09). Antidromic Tachycardia

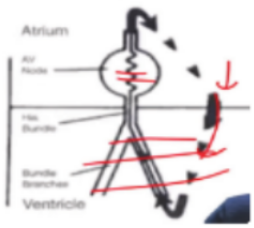

(40:01) Broad QRS Tachycardia : WPW (± Assory Pathway)

FBI

WPW ± · Accessory Pathway. → Fast Broad Irregular. (Ventricular Rate).

- Ventricular Tachycardia
  - ↳ Regular.

Telegram - @Latestpgnotes

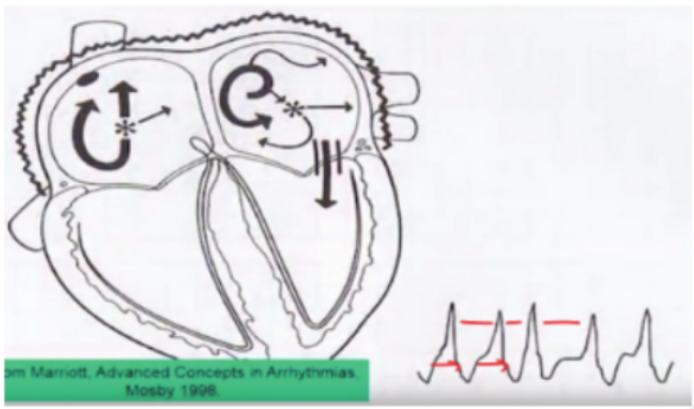

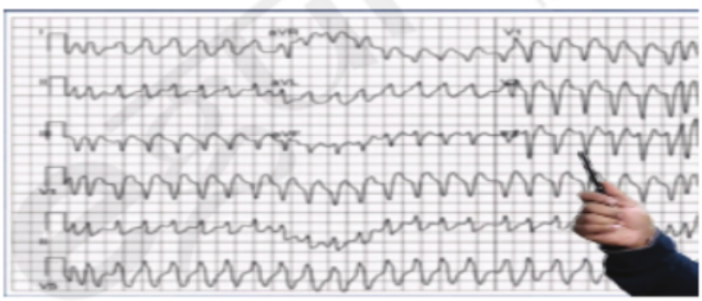

WPW ∈ Risk of Arrythmias : Avoid
- β-Blocker
- CCB (D/N)

Telegram - @Latestpgnotes

WPW → Short PR.
& RS >0.12s.
& wave.

Antiarrhythmics
Class Ia, Ic, III.

H/O Syncope/Collapse/M Symptoms.
↳ Accessory Pathway Ablation.

WPW ≅ SVT → Treat like SVT.
↓
(N).
↓
Treat WPW.

Ectopics.

- Atrial (narrow QRS) → Impulse has to go through AV node
- Ventricular (Broad QRS).

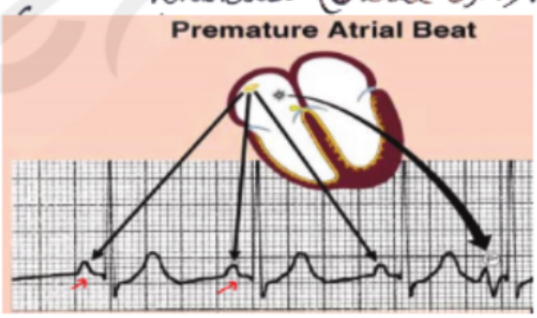

Telegram - @Latestpgnotes

(55:44) Multifocal PVC's : More than One Shape

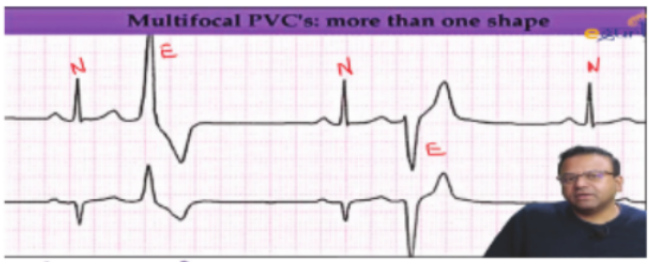

(56:27) → Unifocal : Ventricular Bigemeny

Telegram - @Latestpgnotes

37. Cardiac Arrythmia's 3

(00:19)

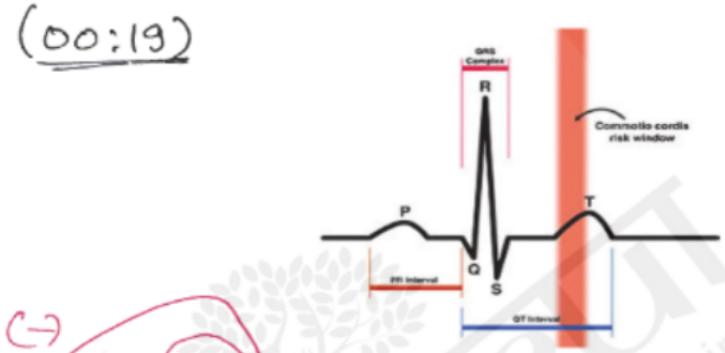

Repolarisation.

(+)

Synchronized Shock → Cardioversion (c R wave)

Shock.

- Synchronized → Cardioversion.
- Non-Synch.
  - Defibrillator.
    - only
      - Ventricular fibrillation
      - Pulseless Tachycardia

Telegram - @Latestpgnotes

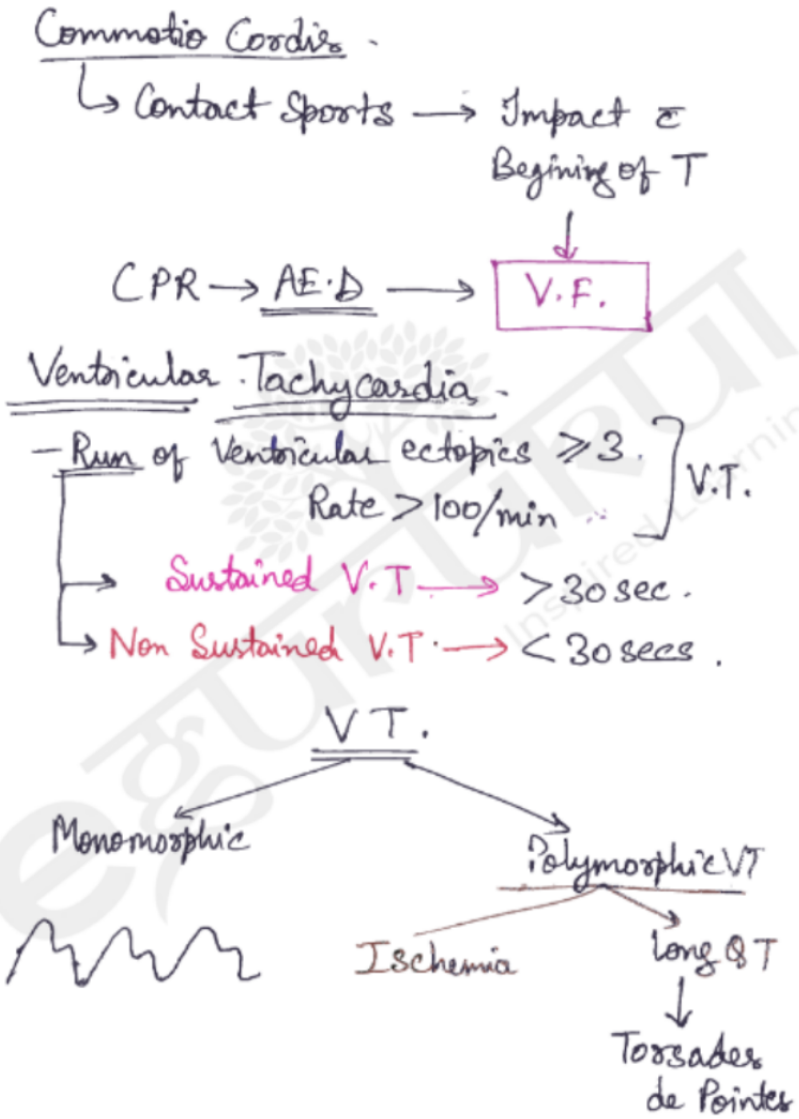

Telegram - @Latestpgnotes

VT

SVT ≅ Aberant Conduction (Branch Block)

Broad QRS-Tachy.

Carotid massage Response (+)

X

X

VT.

Broad QRS Tachycardia

(−)

Axis: N.W. axis.

(+)

(−)

Ventricular foca. ectopi

- Capture Beats.
- Fusion Beats

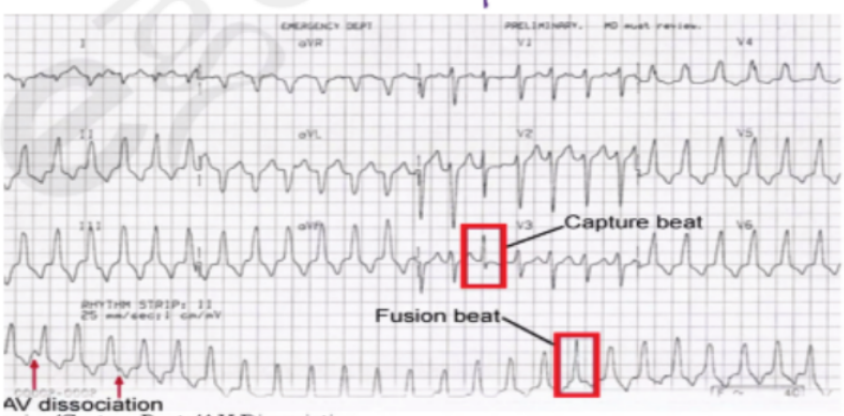

usion/Capture Beats/AV Dissociation

Telegram - @Latestpgnotes

SVT ± Aberrant Conduction	VT
X	→ QRS Concordance ↓ Chest leads.

Rx → Unstable → Shock + lignocaine

Stable :- Amiodarone → Mostly works.

1st → lignocaine. (~~Class III Anti~~ Procainamide.

Long QT.

Congenital ← → Acquired long QT.

T.D.P.

Polymorphic VT

Telegram - @Latestpgnotes

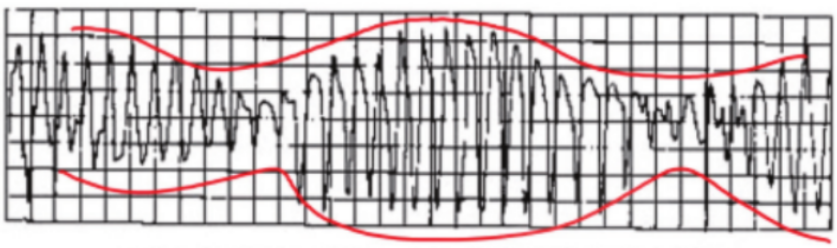

Torsade de pointes ventricular tachycardia

Rx → I.V. → $MgSO_4$.

Polymorphic VT (DOC).

Unstable → Shock.

Ventricular fibrillation.

No Pulse → Next Best step : (Defib) SHOCK.

1st min Shock : 90%

10 min in Shock : 30% Recovery.

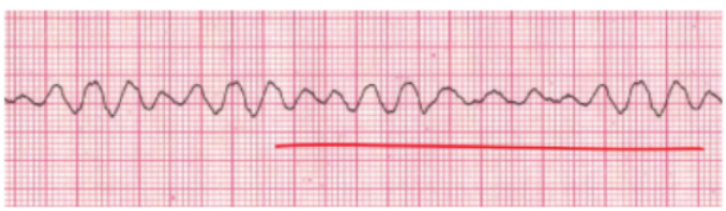

Telegram - @Latestpgnotes

Bradycardia's

Heart Block.

Type 1 ⟶ Prolonged PR.

PR > 0.20 secs.

Type-2 → Mobitz-1 (Wenkebach's) → Missed QRS.

→ Mobitz-2 → Missed QRS.

→ High grade Block.

Mobitz-1: Progressive Prolongation of PR Interval.

Mobitz-2: Fixed PR Interval.

High grade Block:

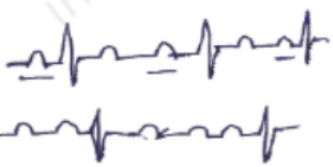

Type-3 ⟶ Complete Heart Block

- R → R interval = equal
- P – P interval = equal

→ No. of P > No. of QRS.

→ No Relationship b/w P ≠ QRS.

Telegram - @Latestpgnotes

Mobitz 2 .
High grade block . } Pacemaker .
Type – 3

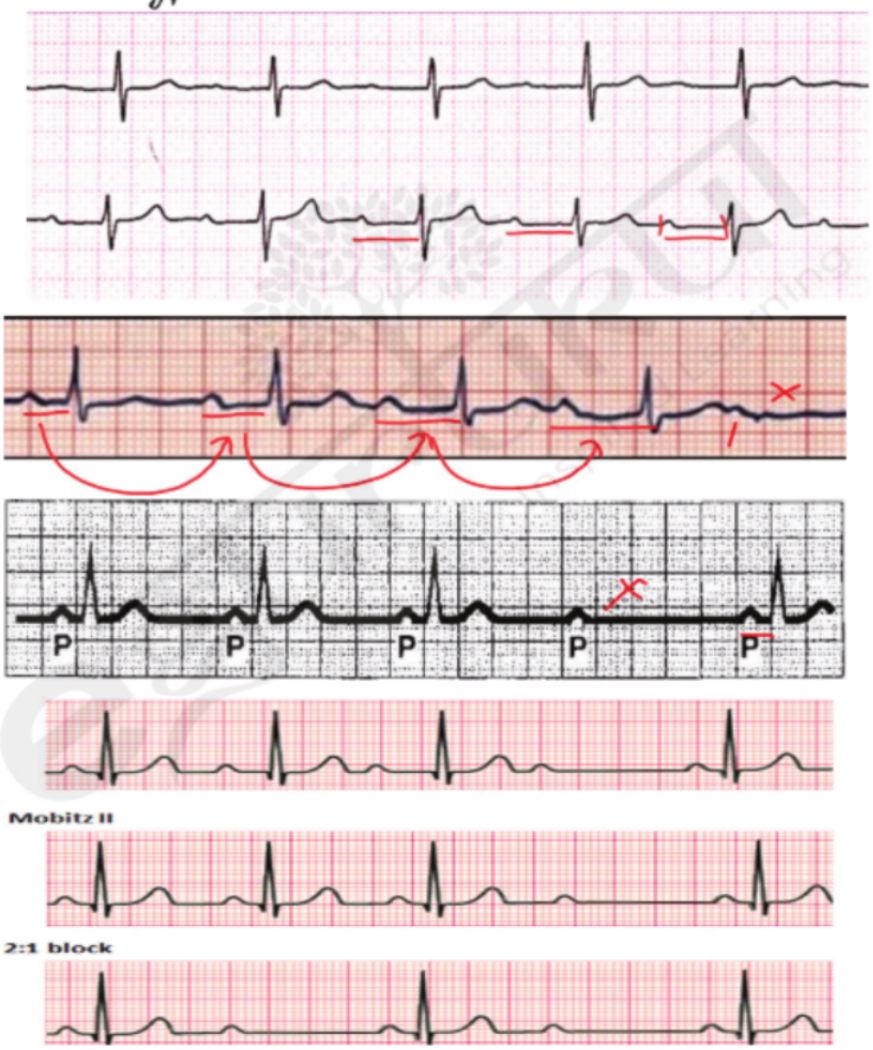

Telegram - @Latestpgnotes

Following pdfs notes are available free →
1 → marrow edition 4 notes(latest optha notes also available) , marrow qbank , marrow pearls
2-> prepladder notes, prep rapid revision 2.0,prepladder treasures 3-> Notespaedia devesh mishra pathology notes, notespaedia marrow Ecg, Notespaedia elite optha
For more
4-> egurukul - - >aswini Kumar anatomy notes, dermatology notes, medicine by thameem sir, ortho notes, physio notes, radio notes(all by notespaedia)
5->all standards books and review books Telegram - @latestpgnotes
6->Notes on demand and many more premium notes are will available free very soon Telegram : @latestpgnotes For more latest notes, join the telegram channel @latestpgnotes
For neet pg discussions join telegram group @neetpgdiscussion
For more latest notes, join the telegram channel @latestpgnotes
Click on link below to join our telegram channel

For more latest notes, join the telegram channel @latestpgnotes For neet pg discussions join telegram group @neetpgdiscussion For group discount upto 40-50% on any lecture app or individual app dm @drnash1

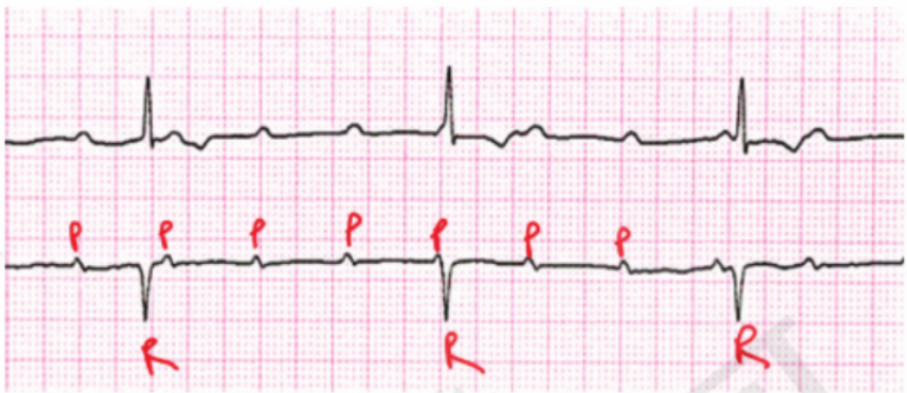

32. ECG PART-8

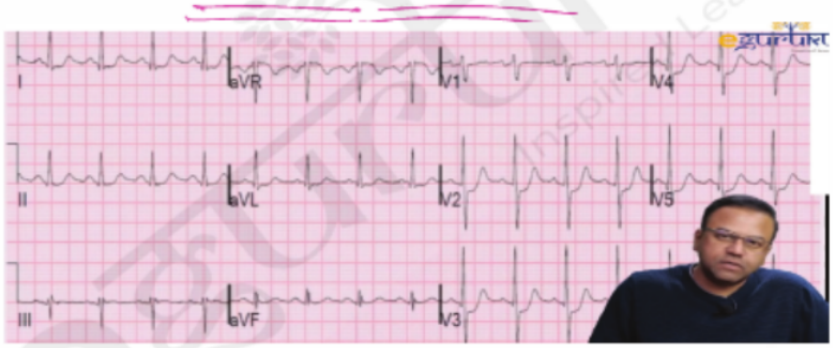

MI → Chest Pain

Easliest Change on ECG: Hyperacute-T waves (Tall)

Telegram - @Latestpgnotes

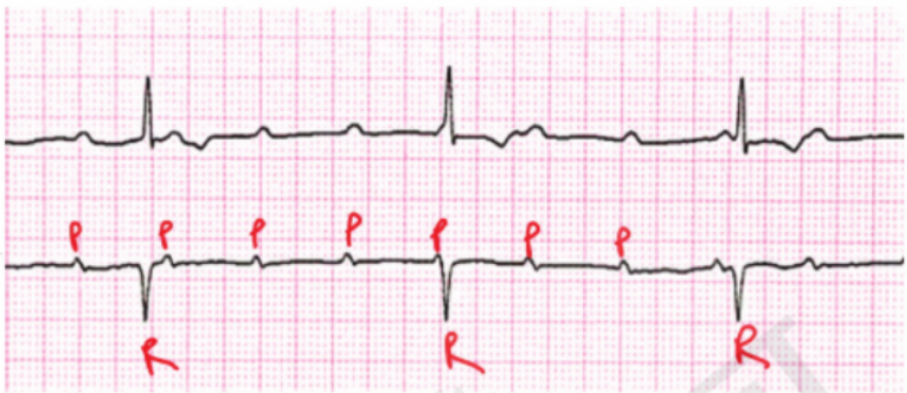

32. ECG PART-8

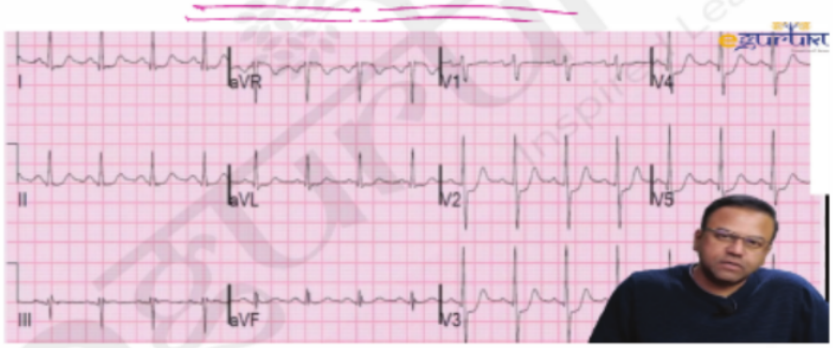

MI → Chest Pain

Easliest Change on ECG: Hyperacute-T waves (Tall)

Telegram - @Latestpgnotes



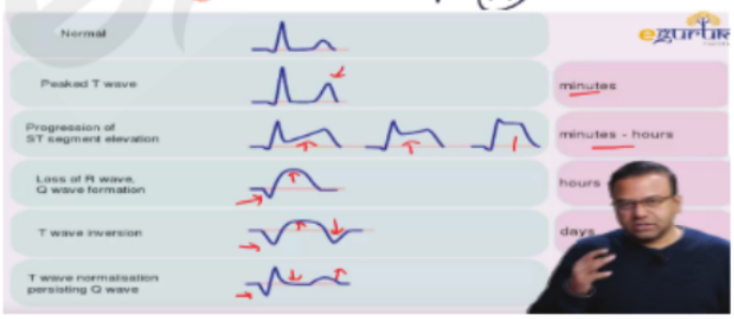

Telegram - @Latestpgnotes

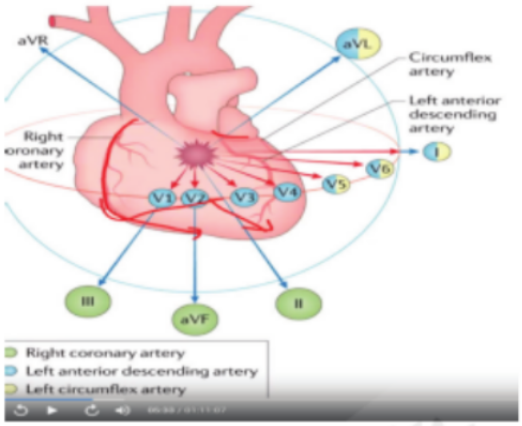

Inferior wall MI → (A) Coronary Artery Main
(B) Circumflex Coronary Artery (Rare)

I, II, III — lateral leads.
AVR.
AVL
AVF
Inferior leads.

V_1 V_2 — Septal leads.
V_3 — Anterior leads.
V_4 → Ant.
V_5 V_6 → lat.

Septal leads. V_1 V_2 → Antero Septal M.I.
V_3 V_4

Chest leads
- Ant. WMI. →
- lat. WMI. → I, AVL, V_5, V_6.
- Antero lateral WMI. → I, AVL, V_3, V_4, V_5, V_6
- Inf. WMI. → II, III, aVF ST↑.
(Limb leads)

Telegram - @Latestpgnotes



Telegram - @Latestpgnotes

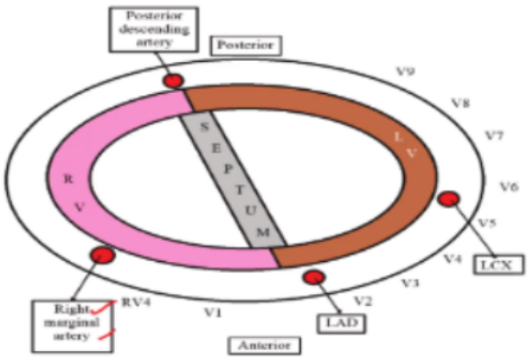

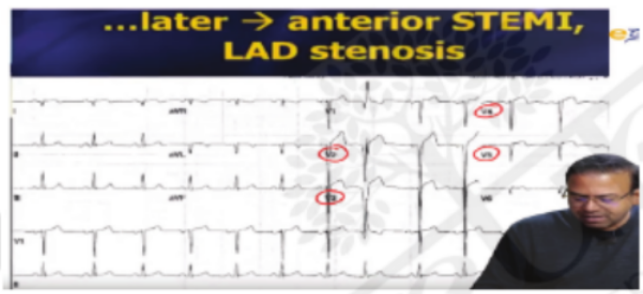

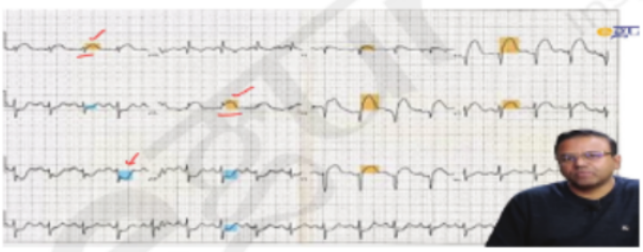

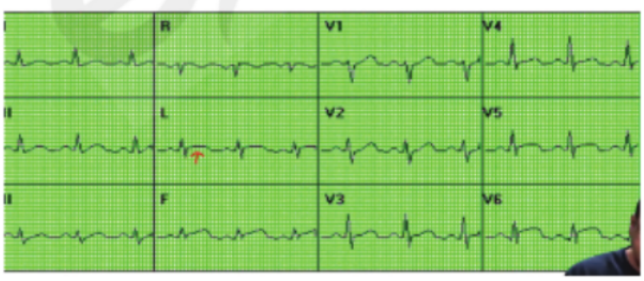

Telegram - @Latestpgnotes

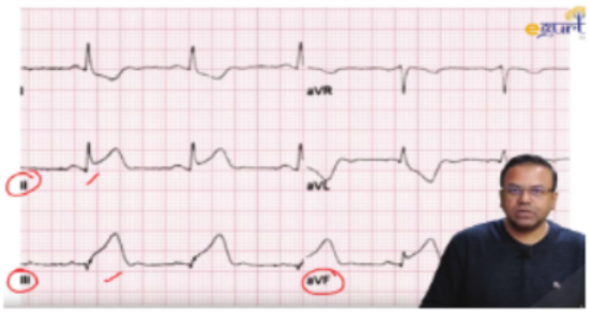

Posterior MI.

→ Tall R waves in V_1 V_2.

- R/S ratio > 1 in V_1 V_2.

→ ST Segment Depression in $V_1 - V_3$.

- Tall, Ant. R waves are mirror image of a pathological, Posterior Q wave.

- Asst. & Inf. WMI.

Telegram - @Latestpgnotes

- Horizontal ST Depression
- Tall Broad R waves (>30 mS)
- Upright T-waves
- Dominant R waves in V_2

Post. wall MI.

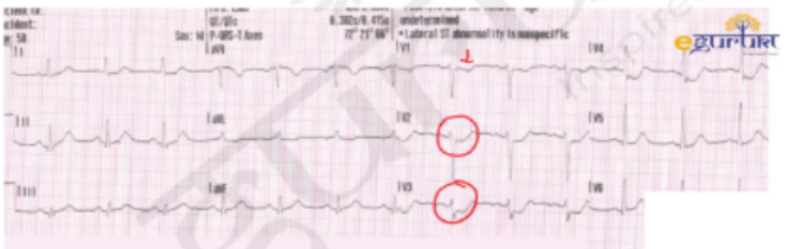

Telegram - @Latestpgnotes

STE → LV Aneurysm.

- Persistant ST↑ cont Reciprocal Changes.
- Rupture is Absent.

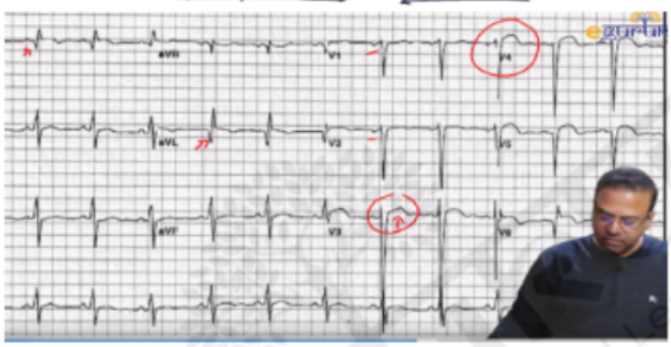

M.I. → ST↑ Pattern. ST↑.

Telegram - @Latestpgnotes

	AMI	Pericarditis/BER
ST↑	Diffuse or localized.	Usually Diffuse
ST↓	STE, Frequent. reciprocal STD	STE, no Reciprocal STD (except V1 or AVR)
ST Morphology.	Straight, Horizontal. Convex or Concave	Concave Upwards
If STE II & III.	STE III > II (Usually).	STE II > III. (almost always)
Evolving Changes.	Usually ST. Segments & Ts	Unlikely in ED.

BER (Benign early Repolarisation)

Telegram - @Latestpgnotes

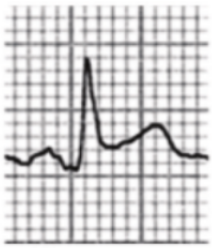

Pericarditis

BER



LBBB

STEMI.

Angina.
Rapidly evolving.
ST↑ – Convex upward
Territorial ST elevation.
Reciprocal ST Depression.
T-Inversion Along ± ST↑
PR – changes Rare.

Acute Pericarditis.

Pleuritic Chest Pain
Slowly evolving.
Concave upward.
Non Territorial.
Nil.
T-Inversion after ST↑
PR Changes Specific

Pericarditis

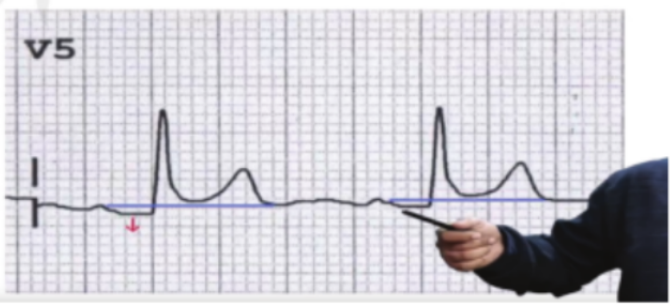

Telegram - @Latestpgnotes

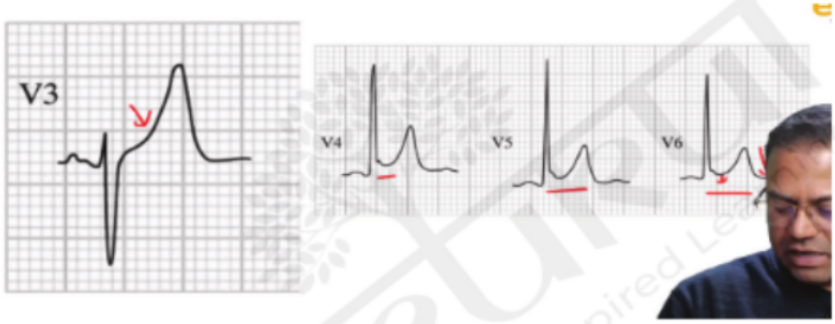

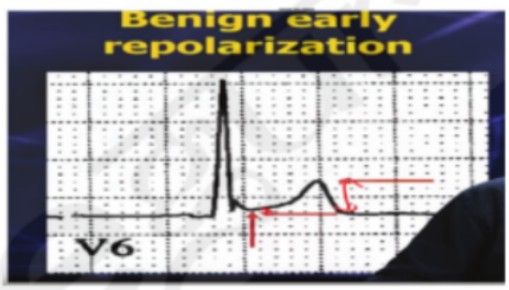

Acute Pericarditis :- • PR Segment ↓ (From Baseline)
- Saddle Shapped ST↑
- PR elevation in aVR & V_1
- Absence of Reciprocal ST↓

Telegram - @Latestpgnotes

Pericarditis

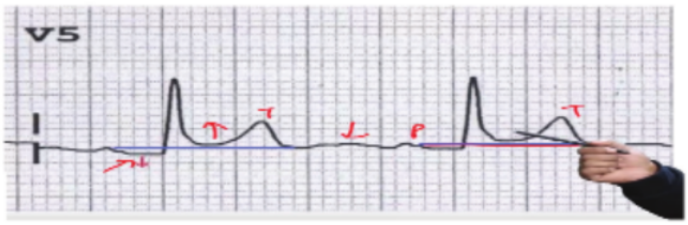

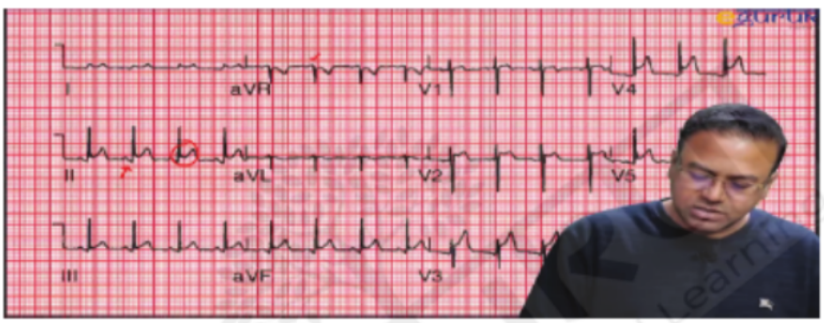

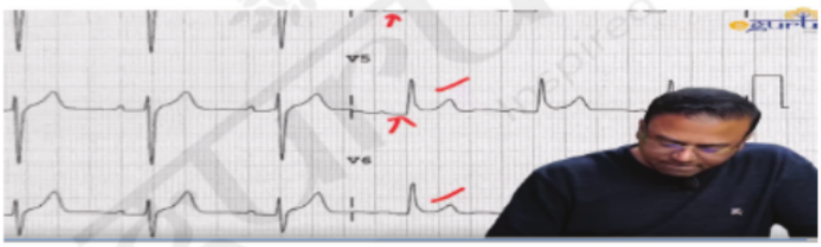

MI

- Pericarditis

Telegram - @Latestpgnotes

ECG & Pericarditis (A.P.)

- Factors that rule in STEMI.
  - → STD except in V_1 or aVR.
  - → (STD(↓) in V_1 or aVR is allowed in AP)
  - → ST↑ in III > II
  - – Horizontal or Convex upwards STE
  - – Q waves that you know are new

BER	A.P.
– ST Segment Height = 1mm	ST Segment = 2mm
– T wave Height = 6mm.	T wave = 4mm
– ST/T wave Ratio = 0.16.	ST/T ratio = 0.5.
– The ST/T ratio < 0.25.	ST/T ratio > 0.25

Telegram - @Latestpgnotes

33. ECG - Part - 9

LVH.

(01:04) LBBB.

Brugada → ST↑ : $V_1 - V_2$.

Curved ST↑.

- Na^+ Channelopathy.

O/E → Syncope.
Arrythmia Development

Telegram - @Latestpgnotes

IWMI.

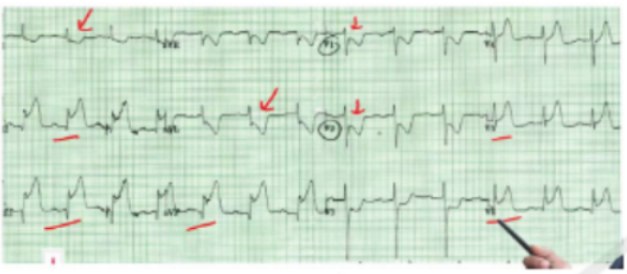

(05:43) Post Wall MI.

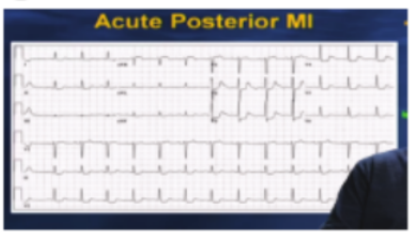

Telegram - @Latestpgnotes

Wallen Sign : → Chest Pain

Type A → Biphasic T waves

Type B → Deep Symmetrical Inverted T

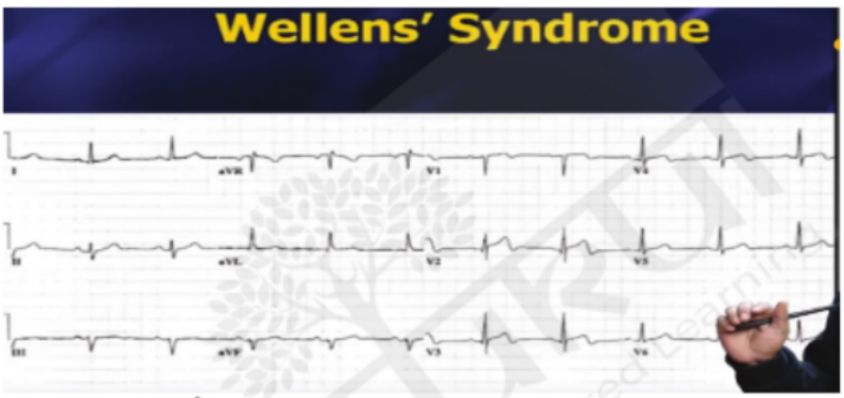

aVR :→ The forgotten 12th lead.

- STE in aVR.

+ STE in aVL → LMCA occlusion

+ ST↑ in V_1 → LMCA or Poximal LAD.

Telegram - @Latestpgnotes

STE aVR ⟶ LMCA Stenosis

- Only Apply this rule when u see Ischemic ST's elsewhere in the ECG.

→ Doesn't Apply to SVT's.

→ Doesn't Apply to Asymptomatic patients without ischemia.

LBBB -

I, AVL
V5 V6
] T↓.

V1 V2
(RBBB T↓) III

ECG 2

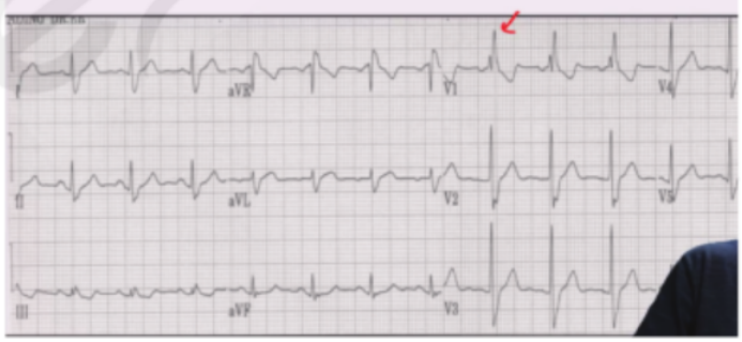

Telegram - @Latestpgnotes

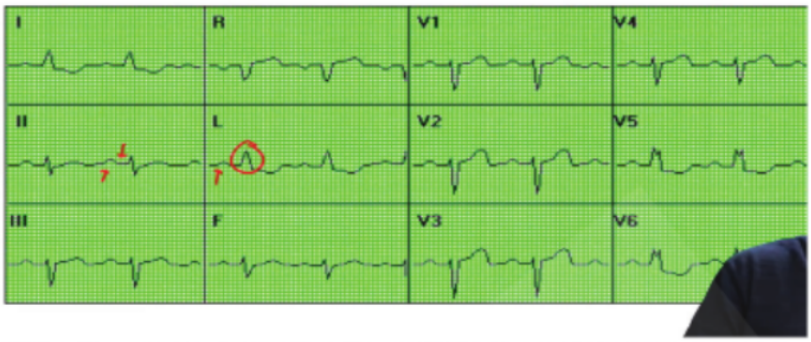

Telegram - @Latestpgnotes

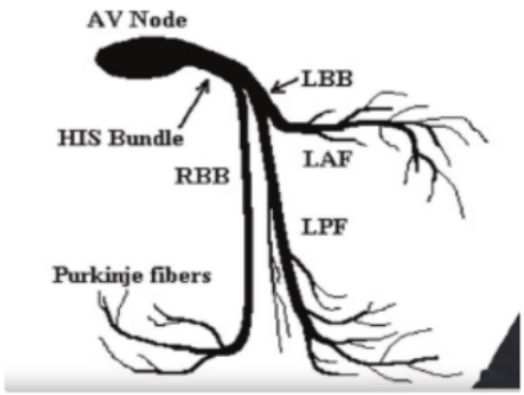

Left Anterior Fasical Block (LAFB) (Hemi).

I, AVL — qR.

Most Common Cause of LAD : LAFB

II, III — rS.

Hemi Blocks.

Left Ant. Hemi Block (opp.) **Left Post Hemi Block.**

- Left Axis Deviation >45
- rS Complexes in II, III, aVF
- qR in I, aVL

- Right Axis Deviation.
- rS Complexes in I, aVL
- qR in II, III, aVF

Telegram - @Latestpgnotes

RAD. : LPFB.

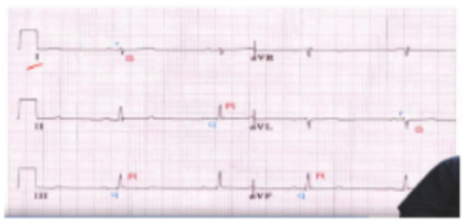

Bifascicular Block. (Ⓝ RBBB → Ⓝ Axis)

RBBB + LAHB → Ⓛ Axis Deviation.

RBBB + LPHB → Ⓡ Axis Deviation

Bifascicular Block

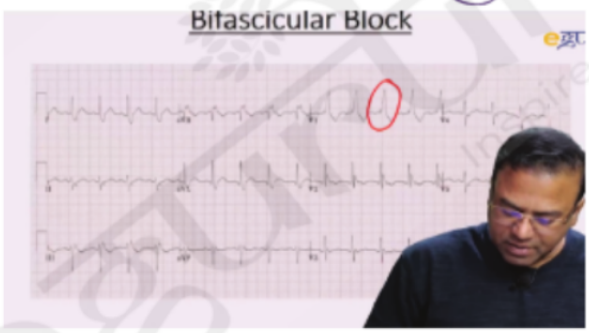

Trifascicular Block.

- RBBB + LAHB + LPHB.
- RBBB + LAD + PR prolongation.
- If Associated with Syncope : Indication PACEMAKER

Telegram - @Latestpgnotes

⇒ RBBB + LAFD + Prolonged PR

ST↑ ≥ 1mm	(L) Heart; $V_4 - V_6$. aVL; I.	Ischemic LBBB upard 'T' (N →)
ST↓ ≥ 1mm in V_1 V_2/V_3	$V_1 - V_3$.	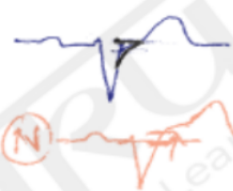
ST↑ ≥ 5mm. $\bar{c}$ Discordant QRS	$V_1 - V_3$.	

Modified 3.

≥ 1 lead $\bar{c}$ ≥ 1mm ST↑ &
Proportionally Excessive discordant ST↑,
as defined by STE ≥ 25% of the depth of
the preceding S-wave (an ST/S ratio of ≤ 0.25).



3/10 = 0.30

Telegram - @Latestpgnotes

~~See~~ Abridged Sgarbossa's Criteria.

ST elevation ≥ 1mm in a lead with a +ve QRS Complex.

Or.

ST depression ≥ 1mm in V_1, V_2 or V_3.

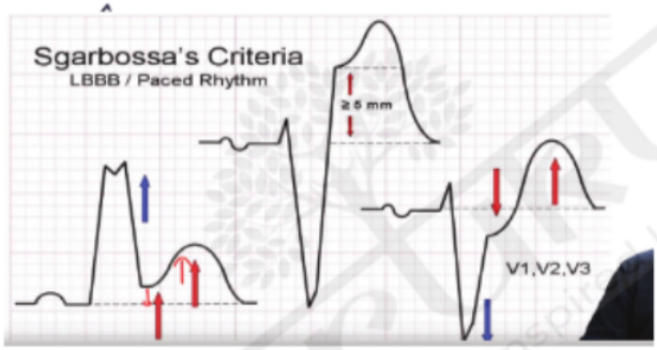

Telegram - @Latestpgnotes

CABRERA'S Sign

Prominent (0.05sec) Notching in the Ascending limb of the S wave in leads V_3 & V_4

Prev. LBBB → MI.

Chapman Sign

Notching ≥ 0.05s of Upslope of the R wave in leads I, AVL or V_6.

Suspected ACS in LBBB

Heart failure, Unstable

Sgabossa ≥ 3 → PCI or lytics

ST/S ratio ≥ 0.25

NO ↓

Serial EKGs, troponin, Abⓝ → Angio

beside echo

ⓝ → Non Invasive Evaluation

Telegram - @Latestpgnotes

34. ECG PART – 10

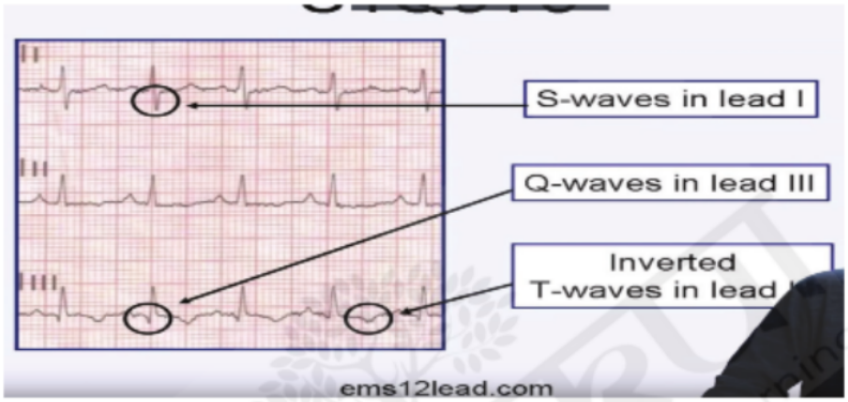

Pulmonary Embolism : S1 Q3 T3.

- S wave in lead I.
- Q waves in lead III.
- Inverted T-wave in lead III (R.V.) wave

• Prolonged Travel H/T ⊕

18. 33 year old obese man with sharp chest pain and dyspnea

Telegram - @Latestpgnotes

Osborn Wave : Hypothermia

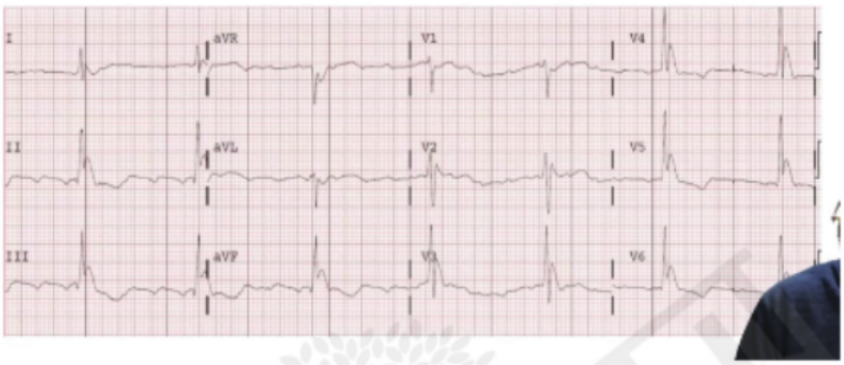

AIVR → 40–120/min.
(Accl. Idioventricular rhythm).

- Broad QRS.
- Atrial activity Absent (No P)
- H/O Treatment for MI (Post MI).
- Reperfusion Arrhythmia (Transient).
- Good.

Junctional Rhythm → Regular Cannon Wave

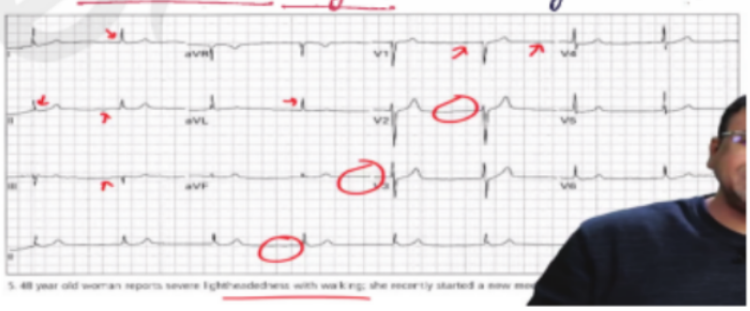

5. 48 year old woman reports severe lightheadedness with walking; she recently started a new

Telegram - @Latestpgnotes

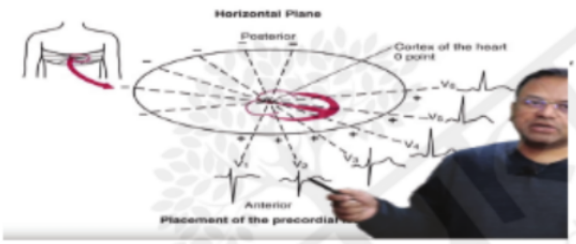

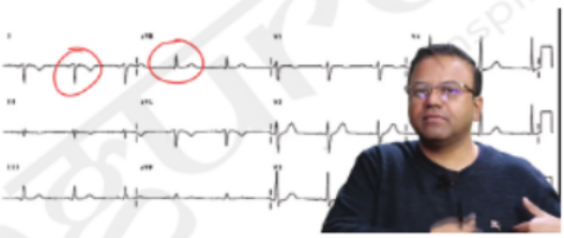

Telegram - @Latestpgnotes

Electrolyte Abnormalities -

- **Hyperkalemia** -
  - Tall T waves
  - Prolonged PR.
  - Broad QRS
  - P - flat - Disappear
  - Sine wave Pattern
  - Sinusoidal.
  - Pauses / Bradycardia
  - Vi fib / Asystole.

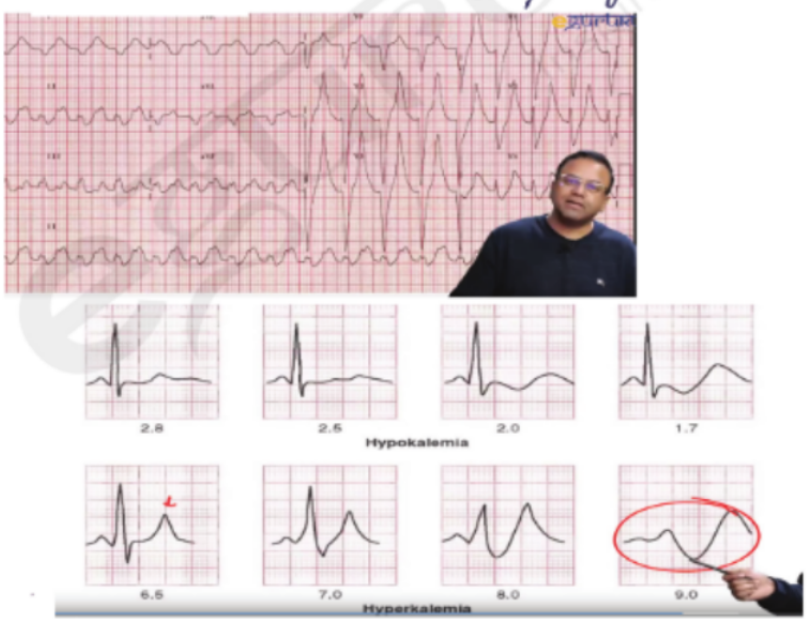

Telegram - @Latestpgnotes

~~Hypothermi~~ Hypokalemia.

U appear.

T- flat.

Inverted T

Roller coster.
(ST↓). Patter.

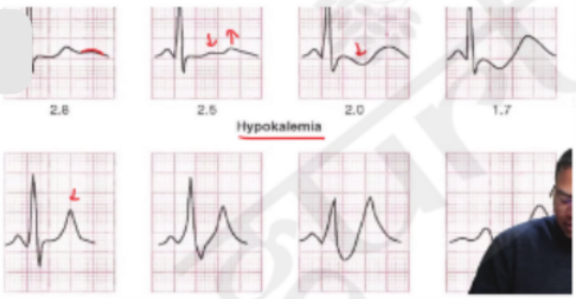

Telegram - @Latestpgnotes

(25:49)

Hyper Calcemia.

Ca 4.7 mg/dl (QTc 653 mS).

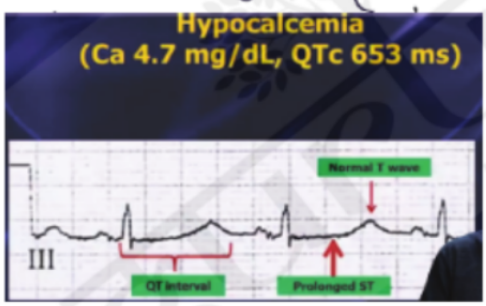

Telegram - @Latestpgnotes

35. HEART FAILURE.

Heart failure is a Syndrome caused by Cardiac dysfunction, generally resulting from Myo-Cardial muscle Dysfuntion or loss & LV

Dilation
Hypertrophy

↓ C.O. → to meet demands of body.

- Exertional Dyspnea.
- Fatigue.
- ↓ SV.
- ↑ filling Pressure

Causes →
- Ischemic H.D.
- HTN.
- DCM.
- RHD – Valvular.

Endocrine.
- Peripartum.
- Non-Rheumatic Valvular.

Telegram - @Latestpgnotes

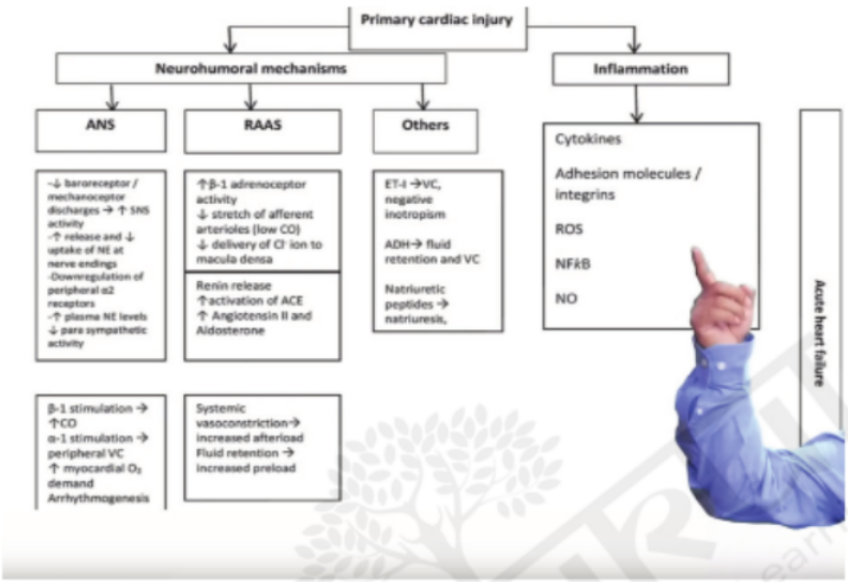

Heart failure.

HF ⊂ ↓EF

EF < 40%

HF ⊂ pEF → Preserved.

EF ≥ 50%

HF mEF → 41-49%
↳ mid.

$EF = \frac{SV \downarrow}{EDV \uparrow}$ ⇒ ↓↓ Systolic funt^{n} Abn^{l}

↓

Systolic Dysfunction. | Dilated.

Telegram - @Latestpgnotes

$EF = \frac{SV}{EDV\downarrow} = \uparrow \geq 50\% \therefore HF_pEF.$

Diastolic Dysfunction

HFpEF → More Common ∴ M > F

25% → HFpEF → F > M.

Survival in heart failure

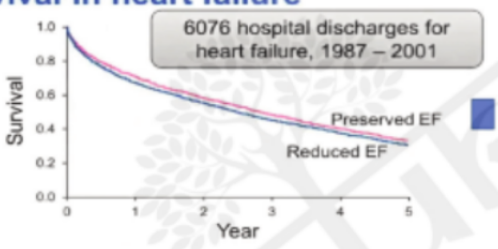

Stages.

Stage A.

- At risk.
  - → Risk factor (+).
  - → Structural Defect Absent.
  - → No Symptoms. → HTN. Diabetes. Family H/O IHD. lifestyle.

Telegram - @Latestpgnotes

Stage-B → Asymptomatic.

Structural Disease ∴ out Symptoms of HF.

– Asymptomatic Valve Disease.

Echo → Ab(n).

Stage C : Structural Defect (+).
Symptoms (+).
∴ Signs of HF.

- Exertional Dyspnea.
- Fatigue.

Stage-D → Refractory.

– HF requiring Specialized Interventions.

→ Rest : Symptoms.

→ Hospitalized Patient.

Suspect : H.F.

- Risk factors (+)
- Exertional Dyspnea.
- Fatigue.
- Orthopnea, PND.

Telegram - @Latestpgnotes

Stage-B → Asymptomatic.

Structural Disease ∴ out Symptoms of HF.

– Asymptomatic Valve Disease.

Echo → Ab(n).

Stage C : Structural Defect (+).
Symptoms (+).
∴ Signs of HF.

- Exertional Dyspnea.
- Fatigue.

Stage-D → Refractory.

– HF requiring Specialized Interventions.

→ Rest : Symptoms.

→ Hospitalized Patient.

Suspect : H.F.

- Risk factors (+)
- Exertional Dyspnea.
- Fatigue.
- Orthopnea, PND.

Telegram - @Latestpgnotes

— Volume Retention ·
- Wt ↑ ·
- Edema → lower Extremity.
- ↑ Abd. girth ·

- Etiology — ?
- Stage & Functⁿ Status · — ?
- Volume Status · — ?

NYHA Classification ·

Class 1 → No limitation of Activity,
Class 2 → Slight limitation ·
Class 3 → Marked · limitation
Stage-C
Class 4 → Symptoms at rest
↳ Stage D.

Telegram - @Latestpgnotes

Volume Status -

→ Wt. gain.
→ Edema.
→ Orthopnea/PND.
→ Ascites, early Satiety.

O/E →

Vitals → Tachycardia, Tachypnea.
BP↓, low Pulse Pressure.

Lungs → B/L Crepts, Pleural effusion.

Heart → S_3, Apical Impulse: Weak
→ Murmur: VHD.

Abdomen → Hepatomegaly, Ascites.

Extremities → Cold → ↓ C.O.
Edema.

JVP↑ → R.H.F.

Telegram - @Latestpgnotes

Investigation.

BNP, NT-Pro-BNP.

- ↑ BNP — Cardiac Cause
- Electrolyte, CBC, Liver enzymes, TSH. lipids.
- CXR.
- ECG: Past Infarction.
  Hypertrophy.
  Arrhythmia.
- Echo → EF, LV Size, Filling Pressure
  Structural Abnormalities.

Telegram - @Latestpgnotes

- Non - Invasive Imaging
- Coronary Angiogram ★

Management → lifestyle Recommendation.
→ Pharmacological.

↓Na ⟶ Na: ≤ 2-3 gm/day.

- Fluid Restriction (≤ 2 L/d).
- Exercise.
- Alcohol: Avoid.
  M ≤ 2 drinks/day.
  W ≤ 1 » /day.

→ Treatment: Sleep disordered Breathing.

Drugs ⟶ • ACE⊖/ARB's.
(↓ Mortality) • β- Blockers.
(↑ Survival) • Aldosterone Antagonists.
• Nitrates/Hydralazine.

↓ Symptoms → Diuretics.
Digoxin.
Inotropes (Dobutamine, Mitrinone).

Telegram - @Latestpgnotes

→ Vasodilators.
↳ NTG, Nitroprusside.
Nesiritide

Stage A-H.F → Reduction of Risk factors.

- Control HTN.
- Smoking Cessation
- Manage lipids.
- Excercise.
- Control wt.
- ACE⊖/ARB's

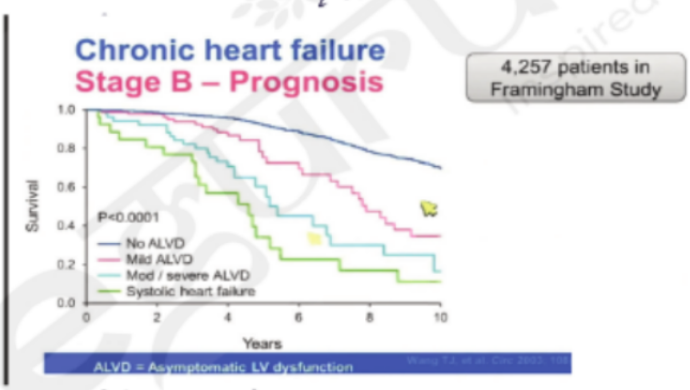

Stage → B-H.F → ACE⊖/ARB's.
- β-Blockers.

Avoid → CCB (D/V).

Telegram - @Latestpgnotes

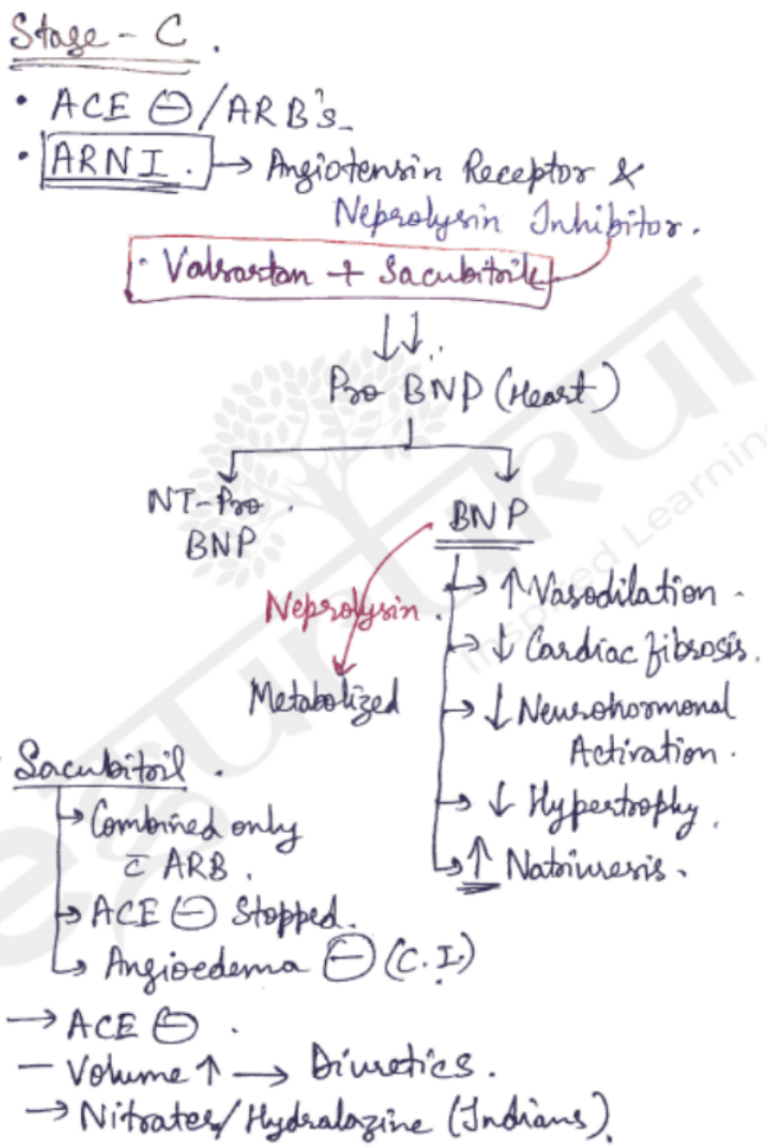

Telegram - @Latestpgnotes

→ EF < 35%. (K^+ < 5meq/L)
($GFR > 30ml/min$.

↓

Aldosterone Antagonist.

Chronic heart failure
Stage C – Therapy

	Initial dose	Goal dose
	Aldosterone antagonists	
Spironolactone	12.5 – 25 mg daily	25 mg 1x – 2x daily
Eplerenone	25 mg daily	50 mg daily
	Hydralazine & nitrates → Use together	
Hydralazine	25 – 50 mg 3x – 4x daily	300 mg divided daily
Isosorbide dinitrate	20 – 30 mg 3x – 4x daily	120 mg divided daily
	Diuretics	
Furosemide	20 – 40 mg 1x – 2x daily	
Bumetanide	0.5 – 1 mg 1x – 2x daily	Consider with right heart failure
Torsemide	10 – 20 mg daily	
Metolazone	2.5 mg 30-60 minutes before loop diuretic	Watch electrolytes Avoid daily dosing

Additional (↓ Symptoms)

→ Digoxin

→ Ivabradine : Inhibit — SA node. (I_f Channels)

↓

Symptomatic : HF, EF.

& HR > 70 – despite β-Blockers.

Stage D → • Heart Transplant.
• Mechanical Circulatory Support

Telegram - @Latestpgnotes

HFpEF.

- BP → ACE⊖/ARB's or β-Blockers.
- Aldosterone Antagonists.
- Diuretics → Euvolemia.
- CAD → Investigated → Rx.
- A. fib → Rx.
- Lifestyle.
- ↑ Volume overload Symp. → Diuretics

Acute Heart Failure.

↑ Vol. overload → Poor Cardiac Output

- Ischemic Symptoms.
- Resting Dyspnea.
- ~~Systemic~~ Symptomatic Hypotension.
- Altered Mentation (↓ B.F. Brain)
- Worsening Renal failure.
- Pul. edema.

Telegram - @Latestpgnotes

- Tachypnea.
- Tachycardia.
- $SaO_2 \downarrow$.
- Crept's.
- Tender Hepatomegaly.
- Pedal edema.

→ Congestion: ↑ JVP
- Crepts.
- S_3 gallop, orthopnea, edema

→ ↓ Perfusion: low Pulse Pressure
Cold → Extremities.
Hypotension.

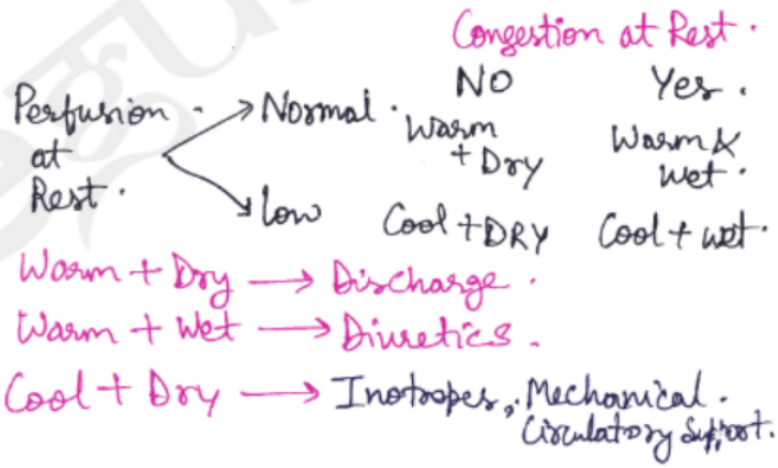

Warm + Dry → Discharge.
Warm + wet → Diuretics.
Cool + Dry → Inotropes, Mechanical Circulatory Support.

Telegram - @Latestpgnotes

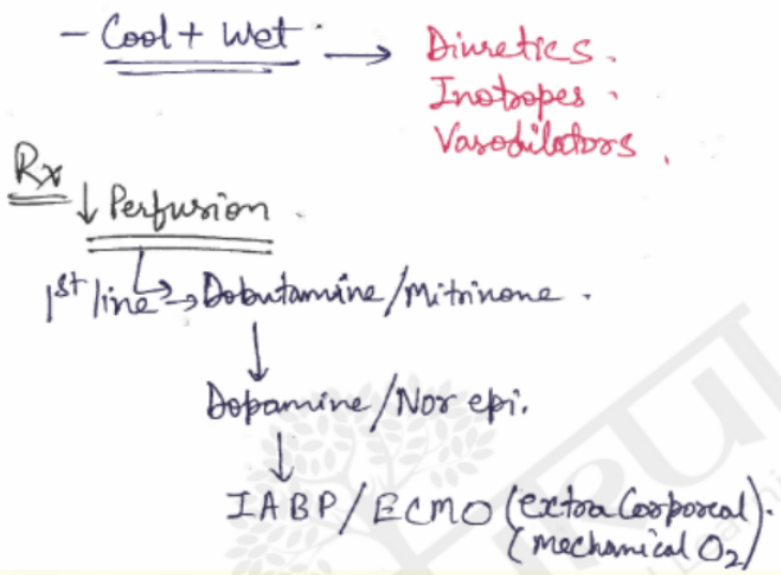

Vasodilators for management of acute heart failure.

	Nitroglycerin	Nitroprusside	Nesiritide
Mechanism	Increase NO synthesis and cGMP	Increase NO syuthesis and cGMP	Activate guanylate cyclase-linked NP receptor A to increase cGMP
Clinical effects	Vasodilator (venous arterial)	Vasodilator (venous = arterial)	Vasodilator (venous = arterial)
Indication	Warm & wet. Cold & Wet. HTN Crises. ACS	Warm & wet. Cold & Wet. HTN Crises	Warm & wet. Cold & Wet
Usual dosing	10-30mcg/min and titrate by 10–20 mcg/min every 10–20 min to max 200 mcg/kg/min	0.1-0.2mcg/kg/min and titrate by 0.1-0.2 mcg/kg/min every 10–20 min to max 2 mcg/kg/min	0.1mcg/kg/min and titrate by 0.005 mcg/kg/min every 3 h. to max 0.03 mcg/kg/min
Onset. Half-life	1–5 min 1–4 min	1 min 10 min	15–30 min 20 min
Elimination	Inactive metabolites in urine (no renal/hepatic adjustment)	Cyanide (hepatic). Thiocynate (renal)	NP receptor C (no renal/hepatic adjustment)

ACS = acute coronary syndrome.cGMP = cyclic guanosine monophosphate.HTN = hypertensive.NO = nitric oxide.NP = natriuretic peptide.

Telegram - @Latestpgnotes

Intra Cardioverter Defibrillator.

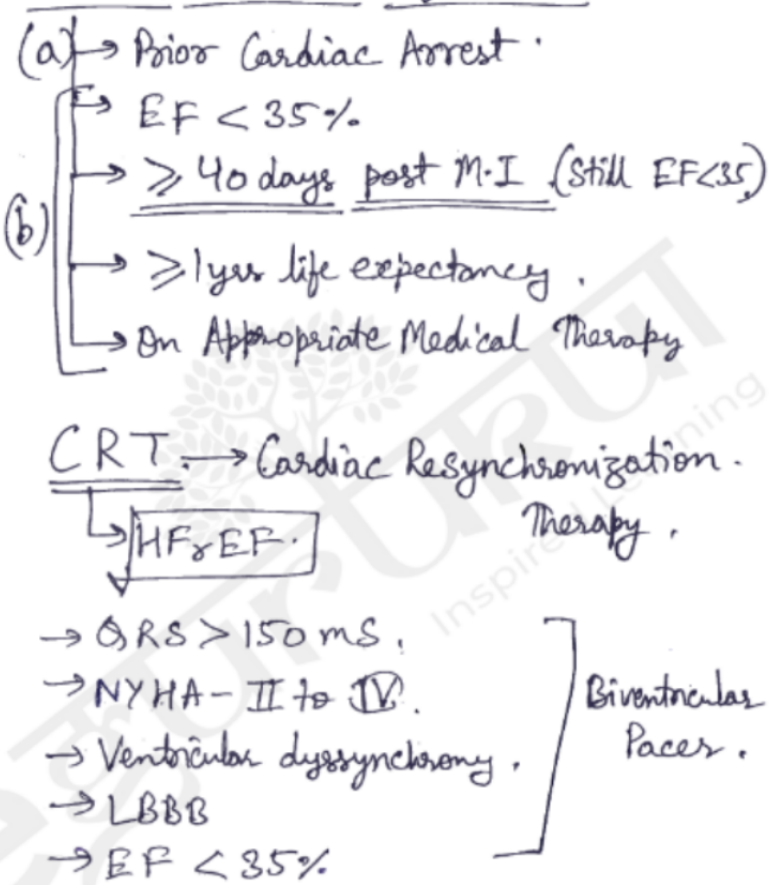

CRT → Cardiac Resynchronization Therapy.

→ HF & EF.

- → QRS > 150 ms.
- → NYHA – II to IV.
- → Ventricular dyssynchrony.
- → LBBB
- → EF < 35%

} Biventricular Pacer.

Telegram - @Latestpgnotes

36 → Cardiomyopathies → 1.

→ Myocardial Disorder of Heart muscle in which there is Structural & functional Abnormality.

∴ Absence of → Coronary Artery Disease
HTN.
Valvular H.D.
Congenital H.D.

Causes:

Genetic.	Mixed.	Aquired
HCM.	DCM.	Myocarditis.
ARVD.	RCM	Stress CM.
LVNC.		Peripartum.
Storage.		Tachycardia.
Conduction.		
Mitochondrial		

Telegram - @Latestpgnotes

Restrictive Cardiomyopathy -

Causes →
- Infiltrative :
  - → Amyloidosis .
  - → Fabry's .
- Non Infiltrative .
  - → Scleroderma .
  - → Idiopathic / Familial .
- Storage Disorders .
  - → Gaucher's .
- → Endomyocardial .
  - ↓
  - Endomyocardial Fibrosis .
    - → Carcinoid .
    - → Serotonin
- HyperEosinophilia
- Metastasis .
- Radiation exposure .
- Drugs → • Anthracyclins .
  - Ergotamine .
- Prior Heart Surgery .

Telegram - @Latestpgnotes

Pathophysiology

Non Dilated Ventricle.

↓

↓ Compliance.

↓

Diastolic Dysfunctn.

↓

↑ filling Pressure.

↓

Atrial Enlargement → Pul. HTN.
(Rt Heart)

↓

CHF (Rt)

O/E → ↑ JVP.
- Rapid 'y' Descent ☆
- S_3

(S_4 – Require Good Atrial kick)

→ DOE
→ Fatigue.
→ Pedal Edema.
→ Ascites.
– Abd. Pain

Telegram - @Latestpgnotes

— Tender Hepatomegaly.

Echo → Enlarged Atria.
↓ filling Pressures.

Amyloid :- Bright → glittering Myocardium.

Eosinophilic :- lacy → Endocardium material. → Thrombus.

$EF = \frac{SV}{EDV}$ > 50% ratio.

Thickness of Pericardium → (N)

Constrictive Pericarditis → THICK.

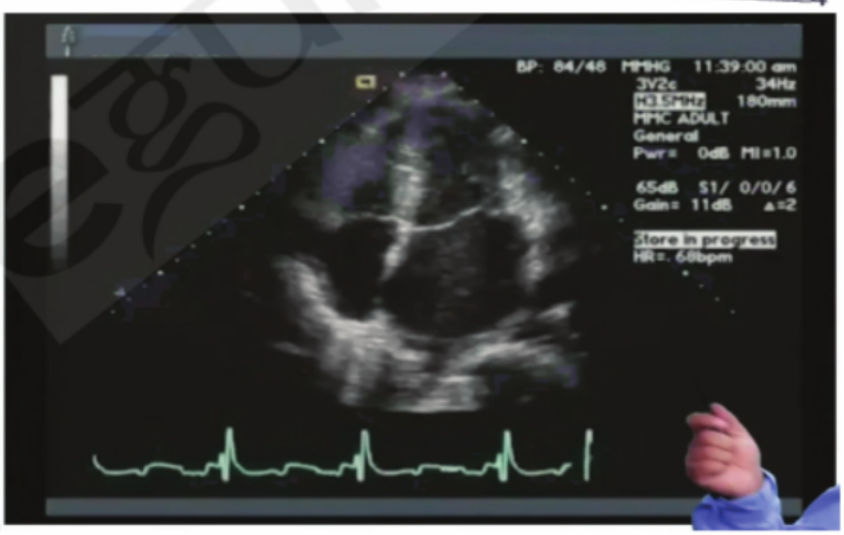

Telegram - @Latestpgnotes

Restrictive Cardiomyopathy -

- Elevated filling Pressure.
- Dip & Plateau Morphology.
- LVEDP > 5 mm Hg + RVEDP.
- RVEDP < 1/3 of LVEDP
- RVSP > 50 mm Hg -
- Ventricular Concordance.

Square Root Sign.
(also in Constrictive Pericarditis)

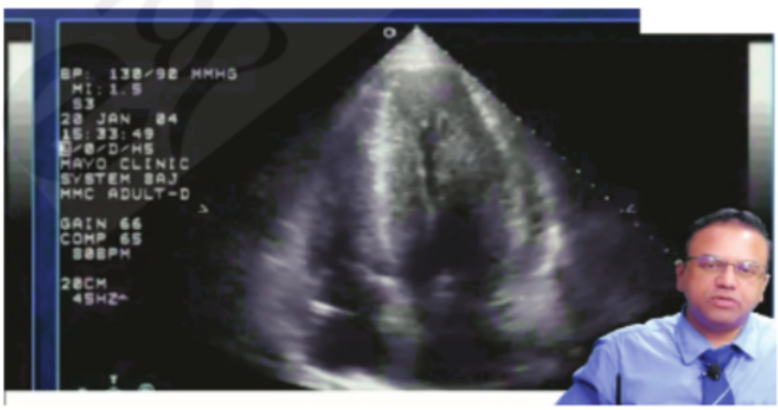

Telegram - @Latestpgnotes

Amyloidosis

→ Wall Thick (Classical for Amyloidosis)
→ Non Dilated LV.
→ Biatrial enlargement.

Types

- AL Type ⟶ Plasma Cell dyscrasia (Amyloidosis)
- ATTR mutation ⟶ Hereditary.
- Wild TTR ⟶ Senile.
- AA type. ⟶ Rare.
  (Sarcoidosis → Systemic)

☆ ATTR Type (Amyloidosis)
↳ Tafamidis ☆

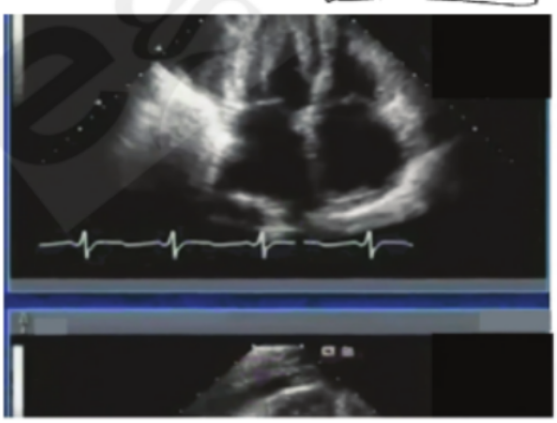

Telegram - @Latestpgnotes

Eosiophilic Cardiomyopathy → Steroids.
→ Anticoagulation

Rx → • Slow Diuresis.
• Cautious β-Blockers

✡ Avoid Digoxin.
→ Treat Underlying Cause.

Dialated Cardiomyopathy

- M.C. Cardiomyopathy.

• ~~Infact~~ Inflammation.

Infective. → Viral Infⁿ (M.C).
→ Parasite → Chagas.
toxoplasma.
→ Diphtheria.
→ Lyme's Disease.

Non Infective →
• Granulomatous
→ Sarcoidosis. (Both Dilated & Restrictive)
→ Hemochromatosis.

Telegram - @Latestpgnotes

- Tachypnea.
- Tachycardia.
- $SaO_2 \downarrow$.
- Crept's.
- Tender Hepatomegaly.
- Pedal edema.

→ Congestion: ↑ JVP
- Crepts.
- S_3 gallop, orthopnea, edema

→ ↓ Perfusion: low Pulse Pressure
Cold → Extremities.
Hypotension.

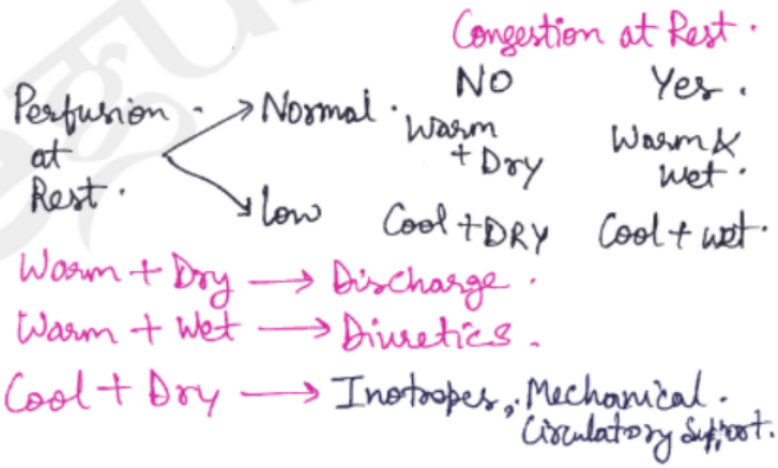

Warm + Dry → Discharge.
Warm + wet → Diuretics.
Cool + Dry → Inotropes, Mechanical Circulatory Support.

Telegram - @Latestpgnotes

→ Eosinophilic Myocarditis
→ Myositis
→ Collagen Vascular Diseases

Toxins → • Alcohol (2nd M.C. after viral).
• Catecholamines ↑
• INF.
• Doxorubicin. ⎫
• Donorubicin. ⎬ ☆
• Trastuzumab. ⎭
• lead / Mercury.

Defficiency → • Selinium ☆
• Thiamine ☆
• Cortinine.

Electrolyte Abn → ↓ Ca ↓ PO_4
↓ Mg

Endocrine → Thyroid
↑ Catecholamine ← Pheochromocytoma
DM.

Telegram - @Latestpgnotes

Dilated Cardiomyopathy
- Obesity.
- Hemochromatosis ☆
- Peripartum Cardiomyopathy ☆
- Chronic Tachycardia's ☆

C/F → DOE
Orthopnea/PND
Pedal edema.
Fatigue.

O/E → Crepts → B/L Chest.
↑ JVP ☆
- S_3
- Apical → Displaced Impulse.

Pulse → low Volume
Dicrotic Pulse ☆
→ Pedal edema.

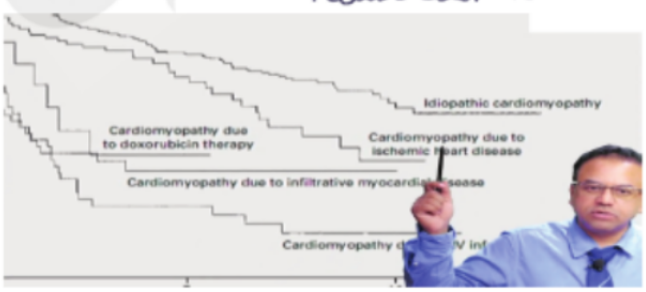

Telegram - @Latestpgnotes

Echo • Dilated Ventricles.

↓

DCM • Functional M.R. (↑ Annulus)
(Secondary).

• EF↓. EF = SV↓ / EDV↑ (=W)

Peripartum Cardiomyopathy

– 3rd Trimester. → 6th month (Post Preg.).

→ Bromocriptine — Rx

Tachycardia. → Sustained
→ DCM.

Telegram - @Latestpgnotes

Chemotherapy Induced

Anthracyclines → Dose depended (≥300)
(Doxorubicin) Irrererrsible

Trastazumab → Non Dose dependent.
Reversible.

5-FU → Vasospasm.
Ischemia, Arrhythmias.

Endomyocardial Biopsy.
↳ For Infiltrative Causes.
(Sarcoidosis).

Initial Evaluation of Dilated Cardiomyopathy (DCM)

Etiology	Evaluation	Caveat
Coronary disease	Coronary angiography or noninvasive testing	Choice of test dictated by pretest probability
Inherited	Detailed family history Genetic testing in selected cases	Common etiology
Endocrine	TSH, Hgb A_1C	Causation not established for hyperglycemia associated DCM
Infectious	HIV, T. cruzi serology in selected cases	
Iron overload	Serum iron, ferritin, TIBC MRI/biopsy in selected cases	Systolic function may be preserved until late in disease
Myocarditis	Endomyocardial Biopsy, MRI in selected cases	Diagnosis may be limited by patchy myocardial involvement

Telegram - @Latestpgnotes

Rx → Treat the Cause.
+
Same as H.F.

Arrythmogenic RV Cardiomyopathy.

- Fatty - replacement : RV-free wall.
- Defect : Desmosomes. (Genetic)

→ Remodelling of Intercalated Disks.

- Avoid Exertion.

↓

Fatty Infiltration + fibrosis.

No t/t.

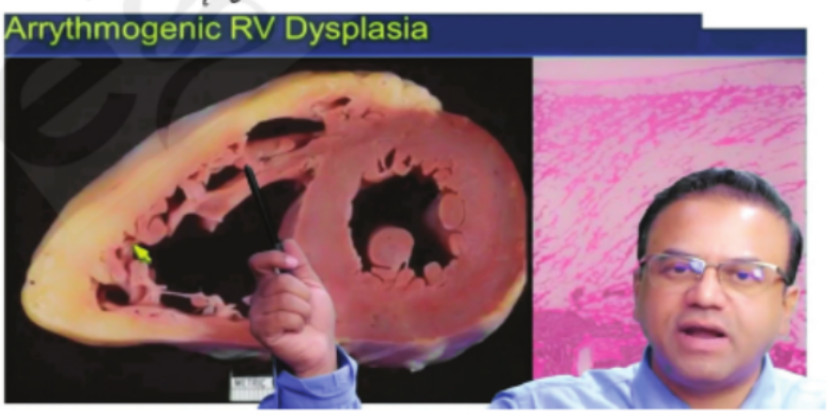

Telegram - @Latestpgnotes

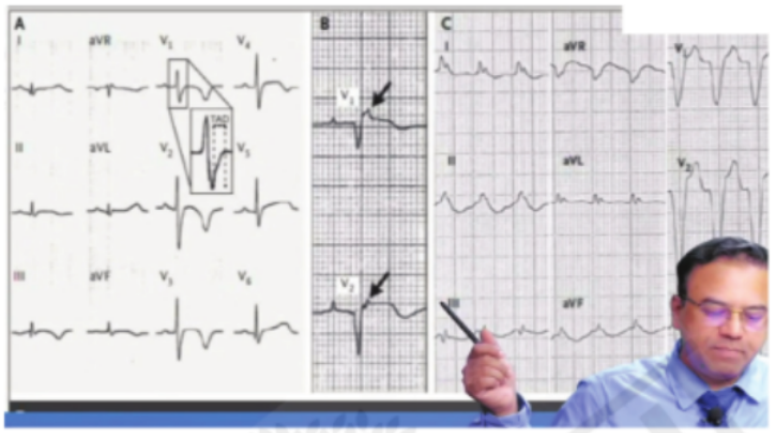

Epsilon waves → Repolarization Abn.
(Chest leads → V_1–V_3).

ARVC (A

↳ Naxos disease (A.R.).

– Cardio Cutaneous Disorders.

- Palmo Plantar Keratosis.
- Wooly Hair.

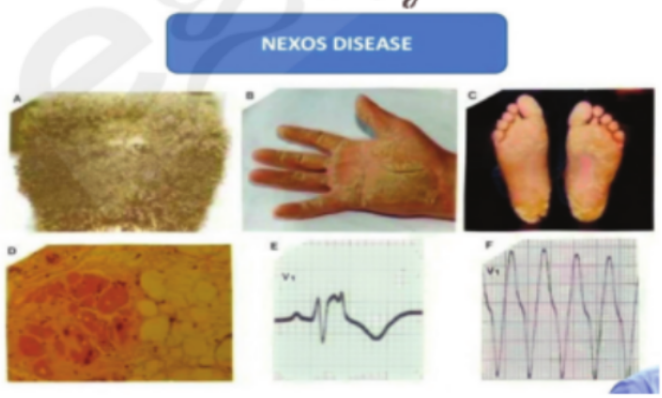

Telegram - @Latestpgnotes

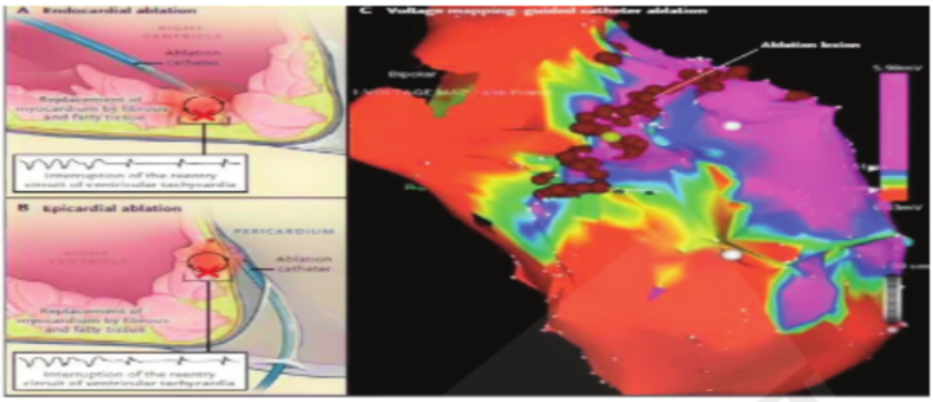

LV - Non Compaction (Genetic).

↳ Inter trabecular Myocardial recesses.

→ ↑ Arrhythmias → Thrombosis (embolic Phenomenon)

→ Heart failure.

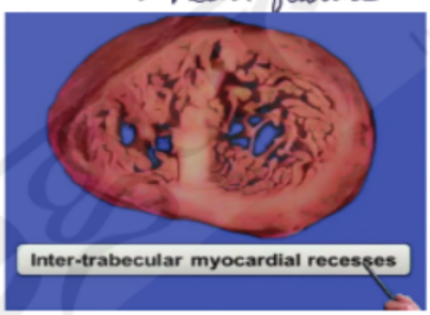

Rx → - Treat Heart failure.
- ICD.
- Warfarin or Anticoagulation.

Telegram - @Latestpgnotes

Stress Cardiomyopathy

(Takatsubo).

→ Broken Heart Synd (Sympathetic)

↑↑ Stress → ↑↑ Catecholamine.

↓

(Rich in β receptors) → Infundibular Spasm. (Aorta)

↓

LV Non Contractility (Mid & Apex LV).

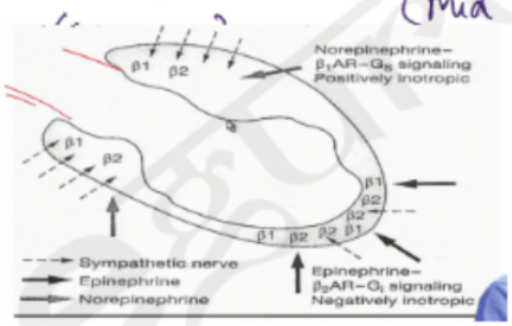

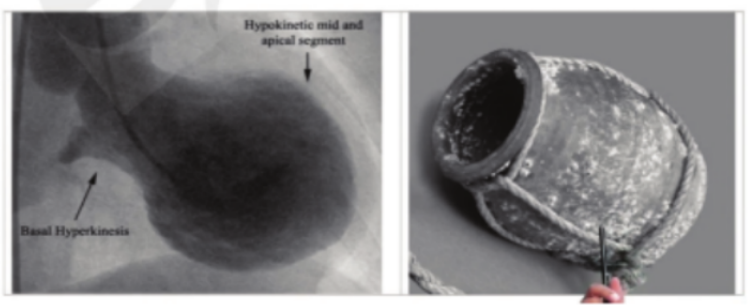

Telegram - @Latestpgnotes

→ ↑ Catecholamine ↑ .

→ Infundibular / Basal → Contraction

→ Apical / Mid Ventricle → Hypokinetic.

⇒ EF↓

→ ECG → ST–T Changes .

↳ ST↑ .

– Chest Pain .

– ↑ Troponin .

: Post Sad news / Emotional Stress

→ F > Male .

Angio → No Occlusion .

• Stunned Myocardium .

Rx → β-Blockers .

ACE ⊖ .

Prognosis :– Good .

Telegram - @Latestpgnotes

37. HYPERTROPHIC CARDIOMYOPATHY

(PATHO-MEDICINE)

— Heart Muscle Disease.

- Heterogenous Grop of Diseases of Myocardium associated ∈ Mechanical or electrical Dysfunt^{n} Causing ventricular Hypertrophy or Dilation due to a variety of Causes usually genetic.

Classification.

Primary	Secondary
Genetic or Acquired disease of Heart.	Systemic Disorder.

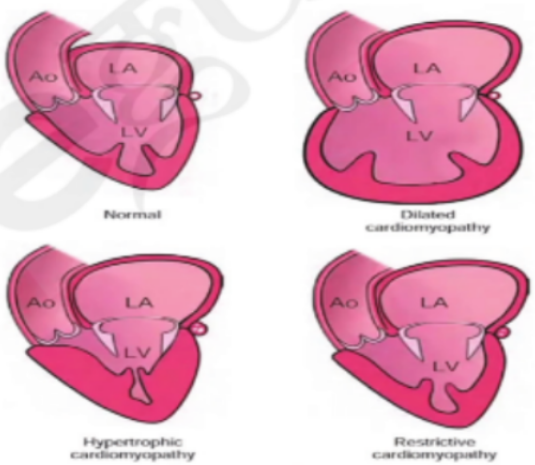

Telegram - @Latestpgnotes

Types of Cardiomyopathies.

(i) Dilated → Systolic Dysfunctn
(Impairment of Contractility)

(ii) Hypertrophic → Diastolic Dysfunctn
(Impairement of filling).

(iii) Restrictive → Diastolic Dysfunctn
(Impairement of filling)

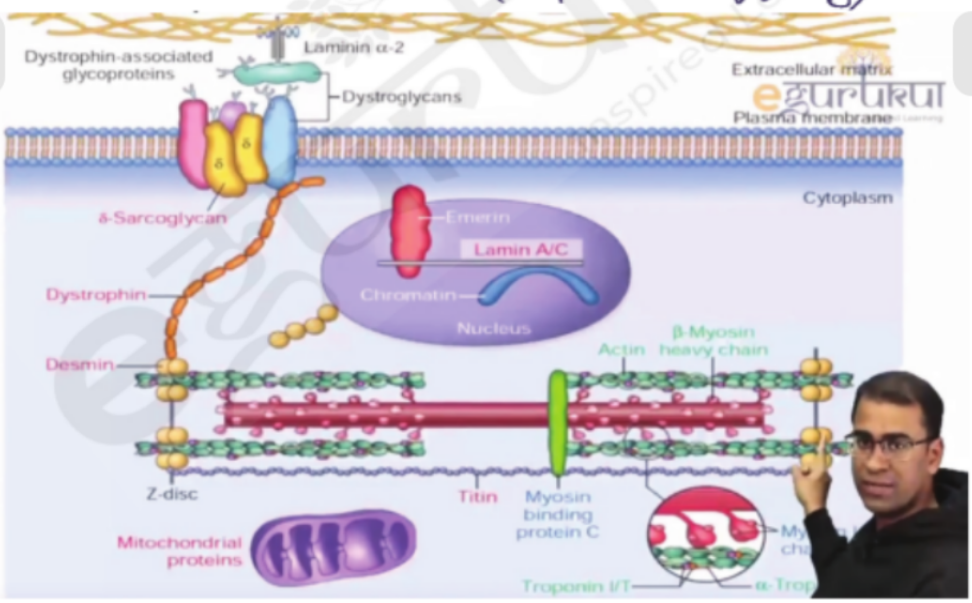

Telegram - @Latestpgnotes

Hypertrophic Cardiomyopathy (HOCM)

Etiology → 100% genetic mutations in Sarcomere Proteins (β - Myosin Heavy Chain β MHC) → M.C.

→ Defect in energy transfer from Mitochondria to Sarcomere.

Other.
- Troponin T
- α - Tropomyosin
- Myosin Binding Protein C.

Morphology

HOCM

Bannana.

(Site → Sub Aortic).

Asymmetric.

Septal Hypertrophy

- Ventricular Septum : L.V. Thickening = 3:1.
- 10% Cases can be Symmetrical.
- L.V. Cavity shows Bannana like Configuration

Telegram - @Latestpgnotes

Microscopic.

- Massive Myocyte Hypertrophy.
  Size > 40 μm (n = 15 μm).
- Haphazardly arranged myocyte fibres.
  (MYOFIBER DISARRAY).
- Interstitial Fibrosis.

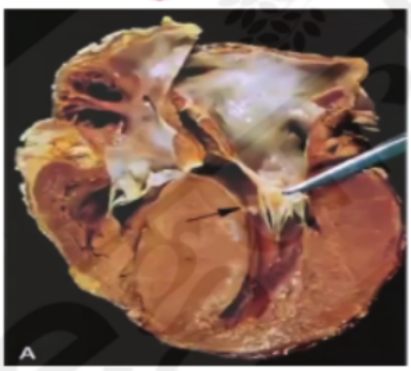

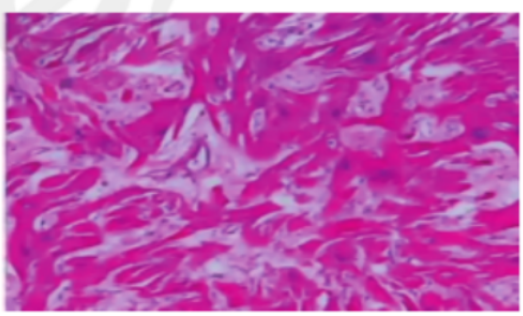

Telegram - @Latestpgnotes

Clinical Features

- LV → Hypertrophy → HFpEF → Pul. Edema
  (Diastolic Dysfunctn)
- → Obstruction (Septal) → Systolic Dysfunctn → Syncope, IHD

→ DOE (M.C. Complaint)
→ Syncope
→ Chest Pain :- Angina

Arrythmias → Palpitations, Syncope, Sudden Cardiac Death (A.D.)

O/E → Pulse → Pulsus Bisferiens
→ Brachial better for Palpation

Apical Impulse :- Double Apical.

Telegram - @Latestpgnotes

Ascultation :- Ejection Systolic Murmur.
(Septal obstruction)

– Aortic Stenosis	HOCM. (Subvalvular A.S).
ESM → Aortic Area. ↓ Carotids (+)	ESM → (+) Parasternal. (Erb's). Does not Conduct to Carotid.
– E.C. (+)	(–ve)
– Pulsus Parvus et tardus	Bifiriens.
– ve.	– M.R. (+) → P.S.M Mitral Area.
±	– Dynamic Auscultation (+)(+)(+)

(↑) → ↑ Blood → louder Murmur.
HOCM → ↓ Blood → louder Murmur.

Telegram - @Latestpgnotes

Murmur → HOCM

- ↓ Blood → ↑ Murmur
- ↑ Force of Contraction : ↑ Murmur.

Standing → ↑ murmur (↓ Blood to Heart).

Valsalva → ↑
Squatting → ↓
Hand Grip → ↓
Nitrates → ↑
β - Blockers → ↓

(Flow to Aorta ↓)
(↓ venous Return).
(↓ obstruction)

Investigations.

Echo → Septal thickness.
LVOT - obst.

★ SAM → Systolic Ant. Motion of M.V.

Telegram - @Latestpgnotes

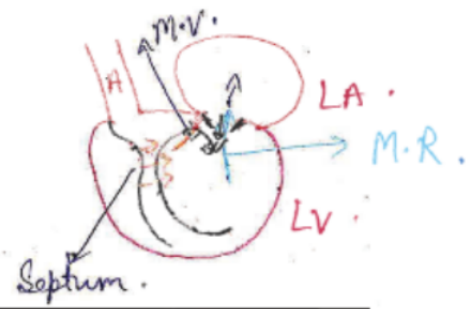

Telegram - @Latestpgnotes

Rx → DOC → β-Blockers.

C.I
- → Diltiazem / Verapamil.
- → Dysopyramide (-ve Inotrope)

Prevent Sudden Cardiac Death → ICD.

- Surgical Myectomy:
  - → Alcohol (Inj.) → Septum.

Sudden Death in HCM.

Risk factors.
- Syncope.
- Family H/O of Sudden Death
- Extreme Hypertrophy (≥ 30 mm)

Most Imp Predictor

- Ventricular Tachycardia
- → L.A. Dilation.
- → Hypotensive response to exercise.
- → late Gadolinium enhancement on MRI.

Telegram - @Latestpgnotes

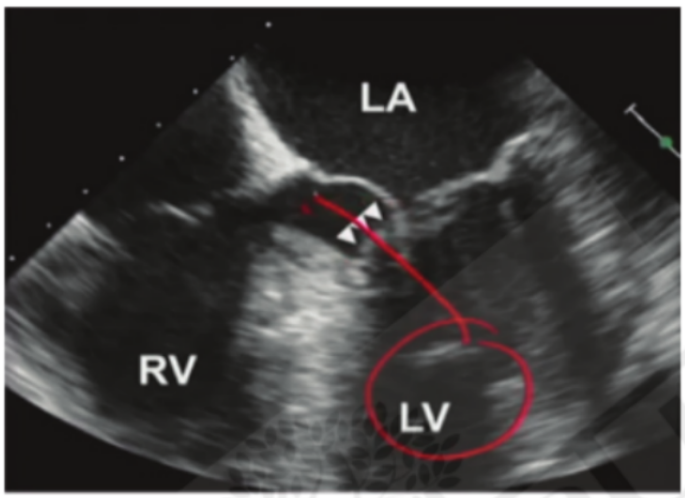

38. PERICARDIAL DISEASES.

- **Acute Pericarditis.**

H/O Sharp Chest pain.
→ Positional variation
↓
Pain ↓ → Patient Sitting/leaning forward.

→ ± H/O Fever.

→ Recent Infection.

Telegram - @Latestpgnotes

O/E → • Pericardial Rub
• Pleural Rub.

Causes →
- Idiopathic
- Autoimmune
- Viral Infectⁿ

Rare →
- Uremia.
- Trauma
- Radiation
- Medications
  - Hydralazine.
  - Minoxidil.
- Malignancy.

ECG → Acute Pericarditis.
- Diffuse ST↑ elevations.
- No Reciprocal Changes.
- ST↑ :- Saddle → Concaving : Upward.
- PR- Segment Depression.

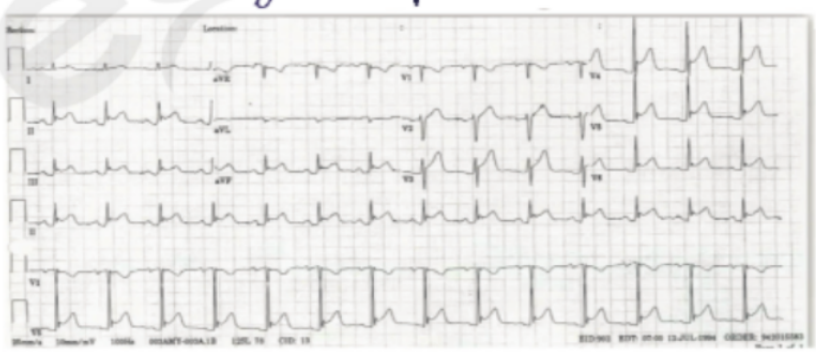

Telegram - @Latestpgnotes

Rx → NSAID's.
+
Colchicine.

Avoid: Steroids.

Dressler: Use Aspirin only.

Predictors of Poor Prognosis.

Major →
- Fever > 38°C.
- Subacute onset.
- Large Pericardial effusion
- Cardiac tamponade
- No Response to NSAID in 1w

Admit & Evaluate

Minor →
- Myopericarditis.
- Immunosuppression.
- Trauma.
- Oral Anticoagulant Therapy.

Recurrent Pericarditis.

1st line → NSAID + Colchicine.

2nd line → Triple Therapy (+ Steroids).

Telegram - @Latestpgnotes

3rd line → Immunomodulation
IV Ip, Anakinra.

4th line → Pericardiectomy.

Tn ↑↑ → MYOPERICARDITIS.

MRI → extensive Myocarditis.

Constrictive Pericarditis

Infections

→ T.B.
→ Viral Infections.
Cox Sackies, Herpes, Mumps, Adeno
HIV.
→ Pyrogenic.
• Pneumococci, Strepto, Staph.
→ Fungal.
→ Syphilis, Parasitic.

Non-Infective → • Idiopathic
• Renal failure
• Malignancy

Telegram - @Latestpgnotes

- Post Radiation.
- Familial Mediterianmion Fever. (FMF).
- Myxedema.

→ RHD

- Collagen Vascular Diseases

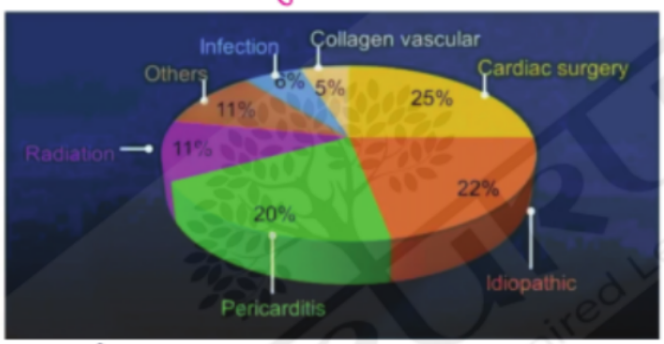

Presentation → • CHF
→ Chest Pain.
→ GI - Symptoms.
→ Arrythmias

O/E → ↑ JVP (Prominent x & y)

- Edema.
- Hepatomegaly.
- Pericardial Knock.
- Ascites.

Telegram - @Latestpgnotes

- Kussmaul's.
- Pulsus Paradoxus

- Thickened wall Restricts Ventricular filling.

Square Root Sign -

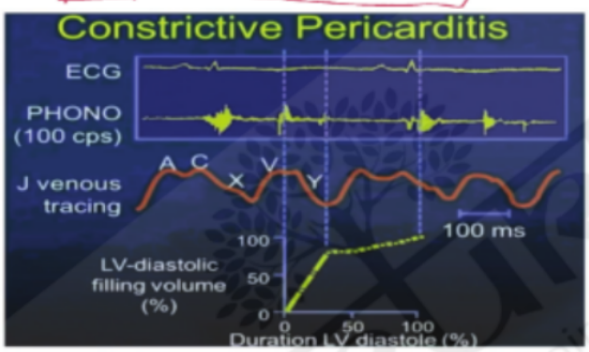

↑JVP on Inspiration.

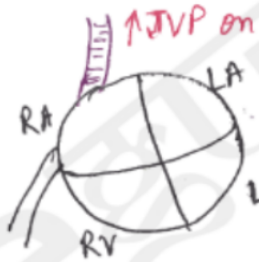

-ve.

Kussmaul's Sign :- ↑ JVP on Inspiration

(Cardiac Tamponade -↓ JVP on Isp.)

Telegram - @Latestpgnotes

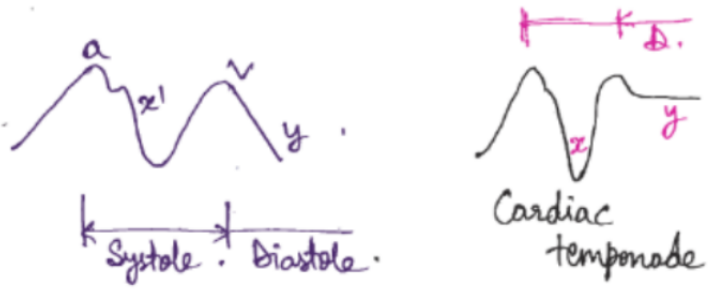

PAY TAX

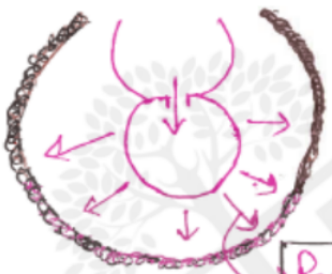

Pericardial Knock.

Telegram - @Latestpgnotes

- DOE.
- RHF → ↑JVP.
  Pedal Edema.
  Tender Hepatomegaly.
  Ascites.

Investigations -

- CXR.
- CT
- Echo.

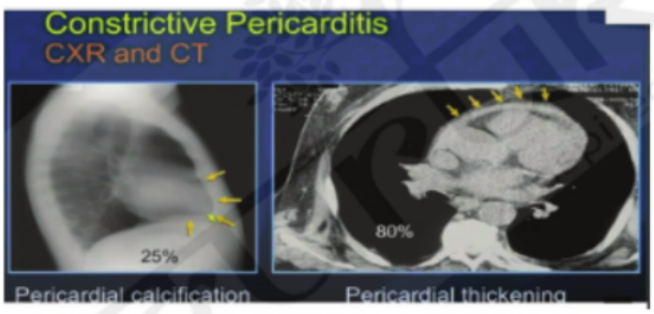

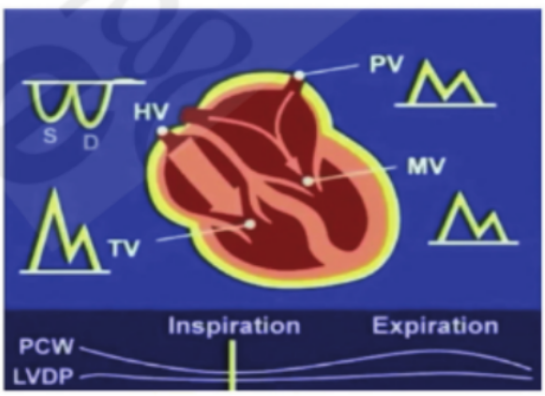

Telegram - @Latestpgnotes

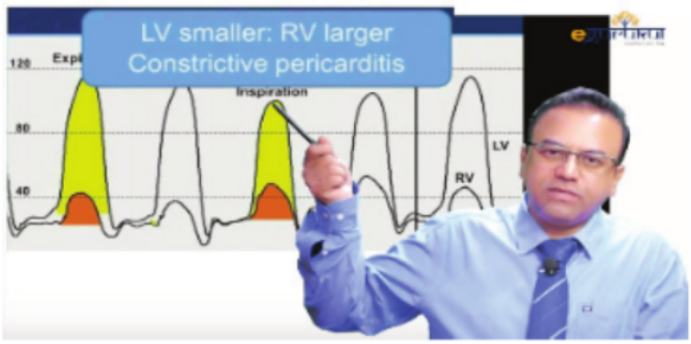

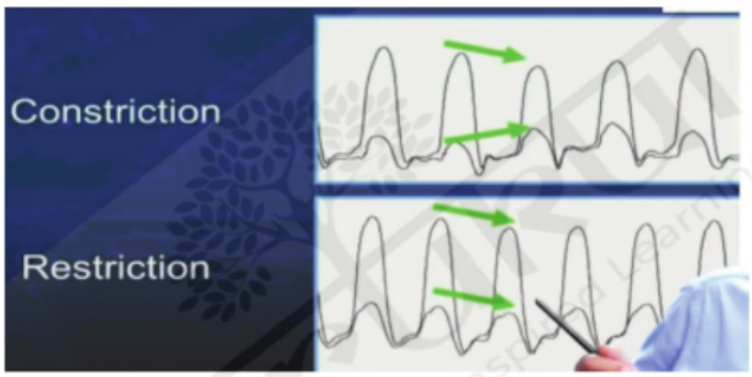

L·A → is not markedly Enlarged (Restricted CM → L·AP)

Rx → Surgery only t/t.

When to Suspect → Const. Pericarditis.

RHF → Out of Proportion to myocardial or valve disease findings.

H/O → Radiation exposure.

Telegram - @Latestpgnotes

- H/O Radiation exposure.
  - Breast Cancer.
  - → Hodgekin's.
- H/O Past Cardiac Surgery (+)

Pericardial Effusion.

(48:56) "Electrical Alternans"

↑↑ Fluid : TAMPONADE.

Beck's Triad. → - ↑ JVP.
- BP ↓.
- Muffled Heart Sounds.

C/O → H.F.
- DOE.
- Fatigue.
- Chest Pain

Telegram - @Latestpgnotes

O/E → • Heart Sounds :- Muffled.
• ↑JVP → Rapid x'
• Pulsus Paradoxus.

CXR → Water Bottle Heart

Echo → - P. Effusion.
- Diastolic Compression → RV
- Late Diastolic Collapse of RA.
- Abnormal Septal Motion.

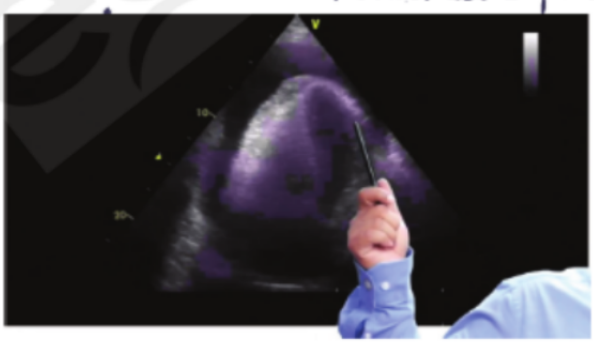

Telegram - @Latestpgnotes

Rx → Pericardiocentesis.
(not Done ∈ Dissection of Aorta)

Constrictive Pericarditis.	Cardiac Tamponade.
• Rapid 'y' x'	Rapid x' – Absent/Prolonged 'y'
• Kussmaul's (+)	– (–)
• Pericardial Knock (+).	– Absent.
• Thickened/Calcified Pericardium	– Absent. Pericardial effusion.
• Pulsus Paradoxus. – 1/3rd	– Paradoxus Pulse. – Most.
• Equlization of Diastolic Pressure. (+)	– (+)

Telegram - @Latestpgnotes

CHARACTERISTIC	TAMPONADE	CONSTRICTIVE PERICARDITIS	RESTRICTIVE CARDIOMYOPATHY
Clinical			
Pulsus paradoxus	+++	+	+
Jugular veins			
Prominent *y* descent	–	++	+
Prominent *x* descent	+++	++	+++
Kussmaul's sign	–	+++	+
Third heart sound	–	–	+
Pericardial knock	–	++	–
Electrocardiogram			
Low ECG voltage	++	++	+
Electrical alternans	++	–	–
Echocardiogram			
Thickened pericardium	–	+++	–
Pericardial calcification	–	++	–
Pericardial effusion	+++	–	–
RV size	Usually small	Usually normal	Usually normal
Exaggerated respiratory variation in flow velocity	+++	+++	–
CT/MRI			
Thickened pericardium	–	+++	–
Equalization of diastolic pressures	+++	+++	–

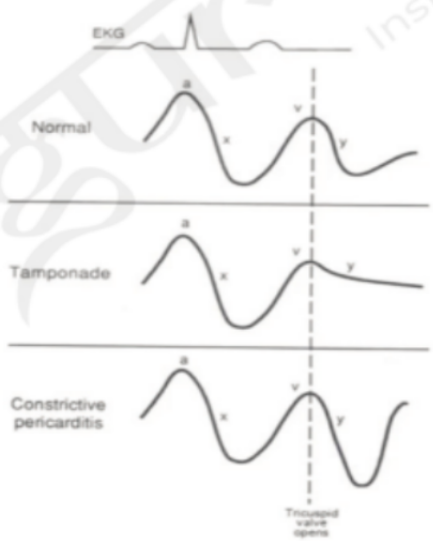

Telegram - @Latestpgnotes

Following pdfs notes are available free →
1 → marrow edition 4 notes(latest optha notes also available) , marrow qbank , marrow pearls
2-> prepladder notes, prep rapid revision 2.0,prepladder treasures 3-> Notespaedia devesh mishra pathology notes, notespaedia marrow Ecg, Notespaedia elite optha
For more
4-> egurukul - - >aswini Kumar anatomy notes, dermatology notes, medicine by thameem sir, ortho notes, physio notes, radio notes(all by notespaedia)
5->all standards books and review books Telegram - @latestpgnotes
6->Notes on demand and many more premium notes are will available free very soon Telegram : @latestpgnotes For more latest notes, join the telegram channel @latestpgnotes
For neet pg discussions join telegram group @neetpgdiscussion
For more latest notes, join the telegram channel @latestpgnotes
Click on link below to join our telegram channel

For more latest notes, join the telegram channel @latestpgnotes For neet pg discussions join telegram group @neetpgdiscussion For group discount upto 40-50% on any lecture app or individual app dm @drnash1